

Avances en Imagen de Epilepsia

Juan Alvarez-Linera Prado

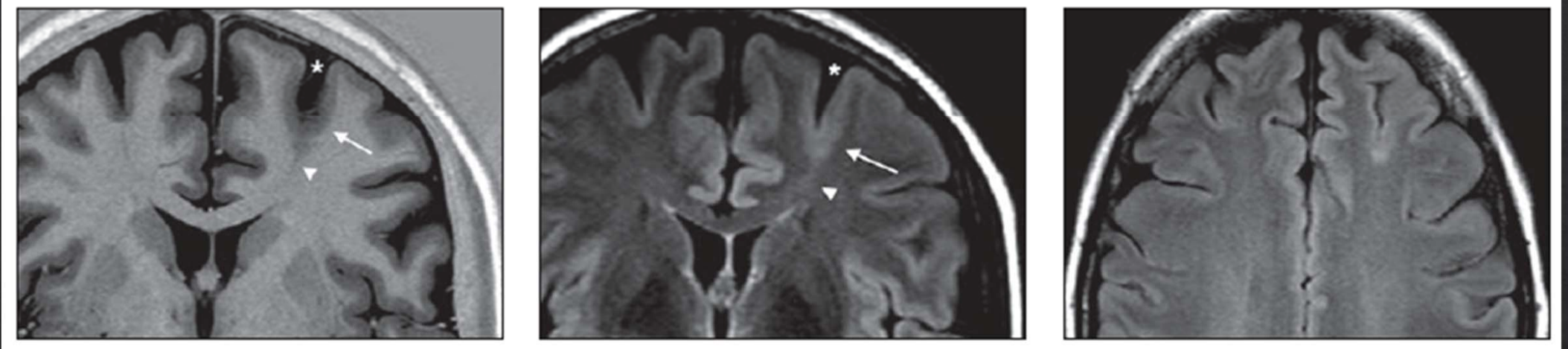
Hospital Ruber Internacional

Avances en Epilepsia

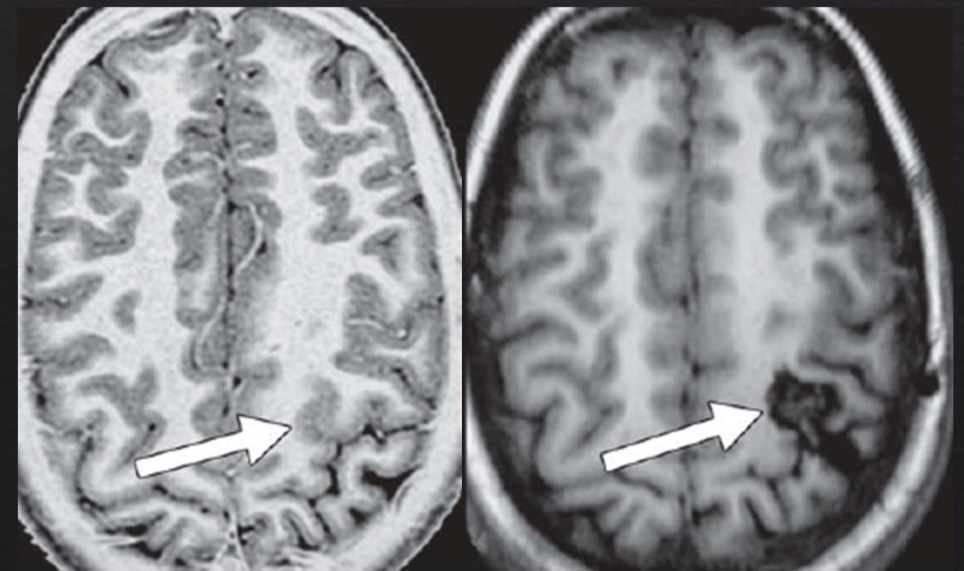
- ◇ Displasias corticales PEQUEÑAS
 - ◇ La mayoría: FONDO DE SURCO
 - ◇ Difícil detección (S 50%), excelente pronóstico Q
 - ◇ PET/RM (ASL: alternativa, complemento)
 - ◇ Localiza la lesión
 - ◇ Segunda lectura de RM
- ◇ Displasias SUTILES
 - ◇ RM 3T negativa o dudosa
 - ◇ Estudio SELECTIVO: 2-D (mayor contraste/resolución)
- ◇ RMf/Tractografía: planificación Q
 - ◇ Posible en niños (entrenamiento, Resting S)
 - ◇ Menos Electrodo Subdurales
 - ◇ Cirugía EN áreas elocuentes

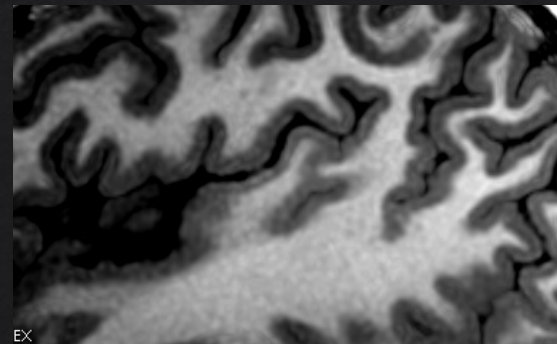
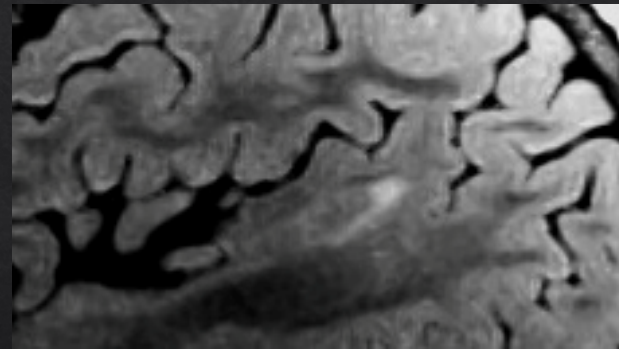
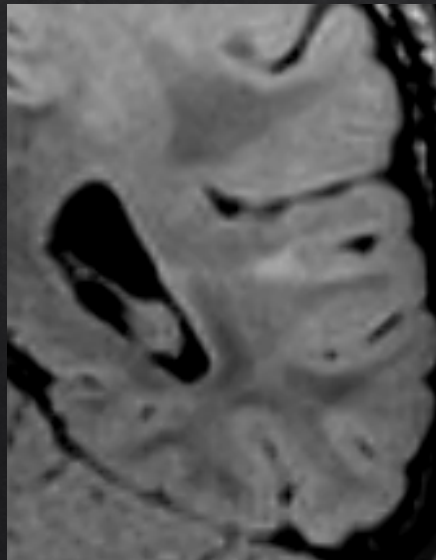
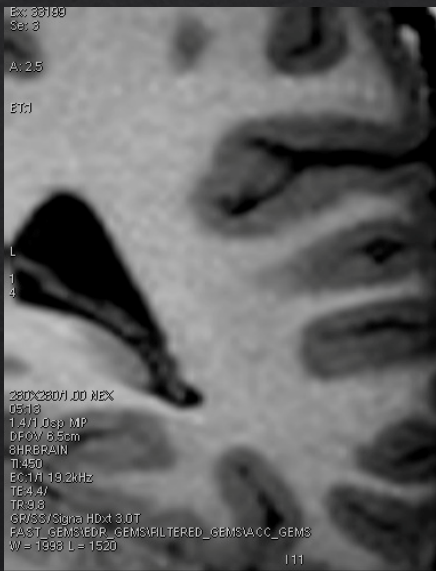
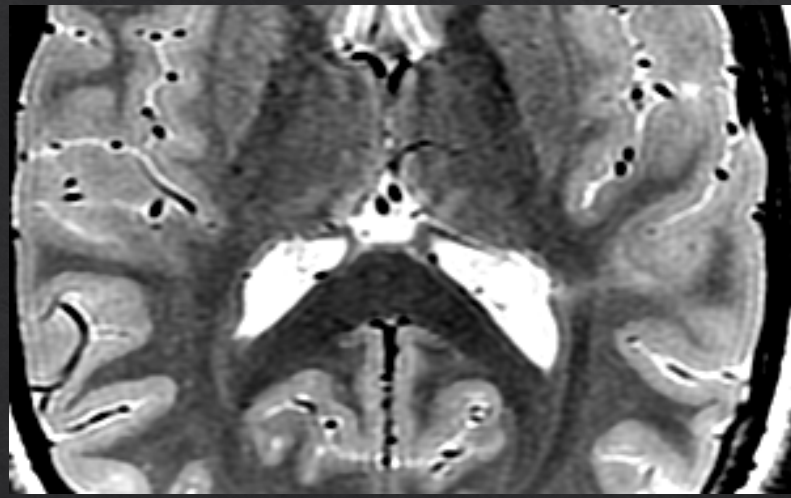
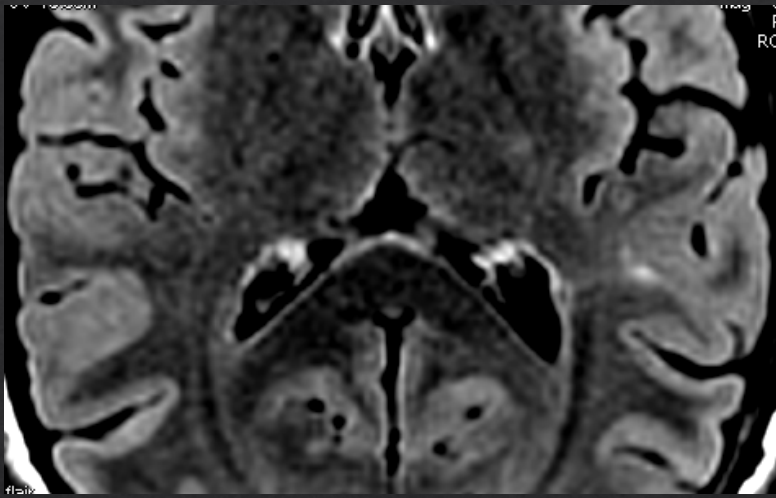
Bottom-of-Sulcus Dysplasia: Imaging Features

Hofman, Fitt, Harvey, Kuzniecky, Jackson AJR 2011



CONCLUSION. Bottom-of-sulcus dysplasia is a **distinctive malformation** of cortical development that can be diagnosed on the basis of imaging characteristics. **Reliable identification** of this type of malformation of cortical development is **difficult but clinically important** because the lesion appears to be highly epileptogenic and because the prognosis for **seizure control is excellent** after focal resection.

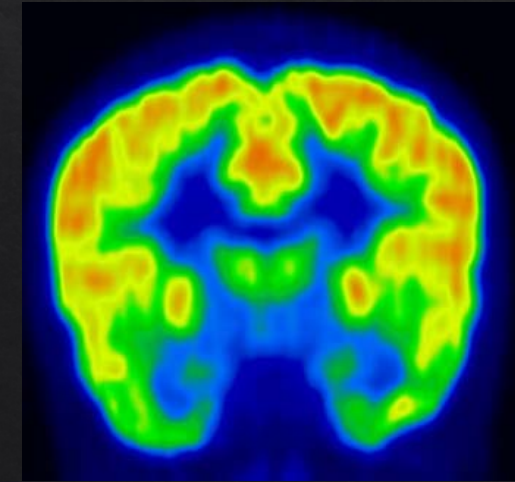
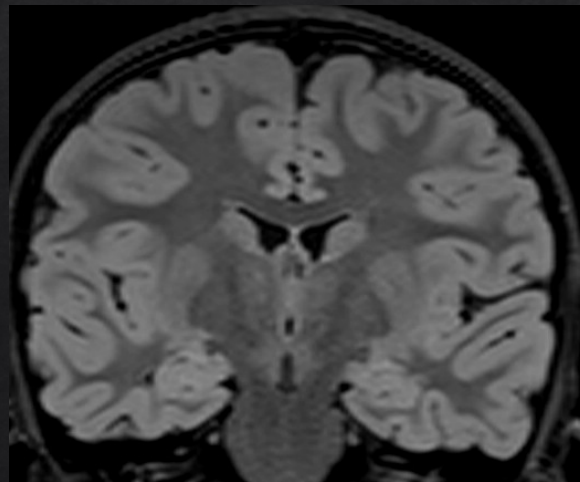
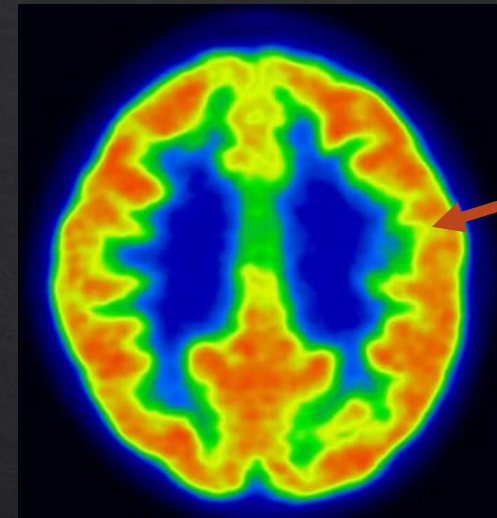
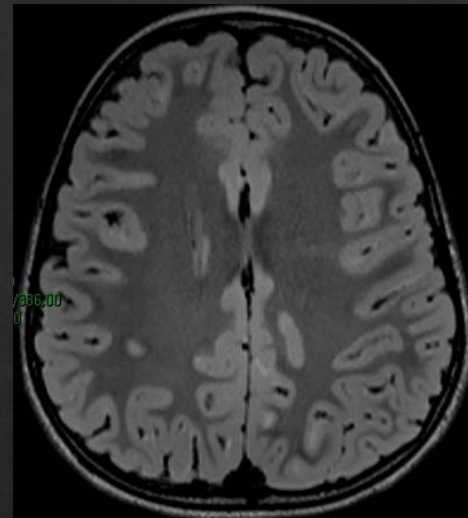
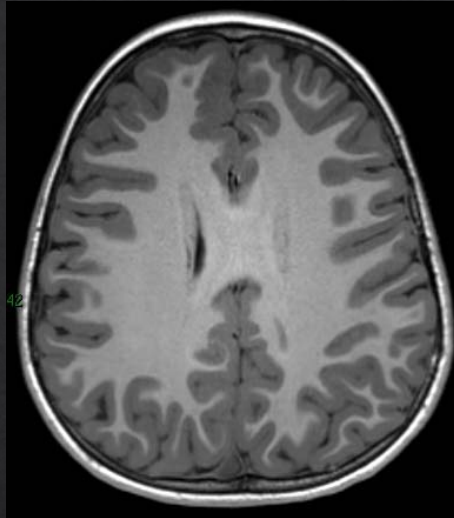




Small DCF: High Rz, Fusion PET/MR

Small FCD (bottom of sulcus): Difficult to detect but excellent surgical result when detected

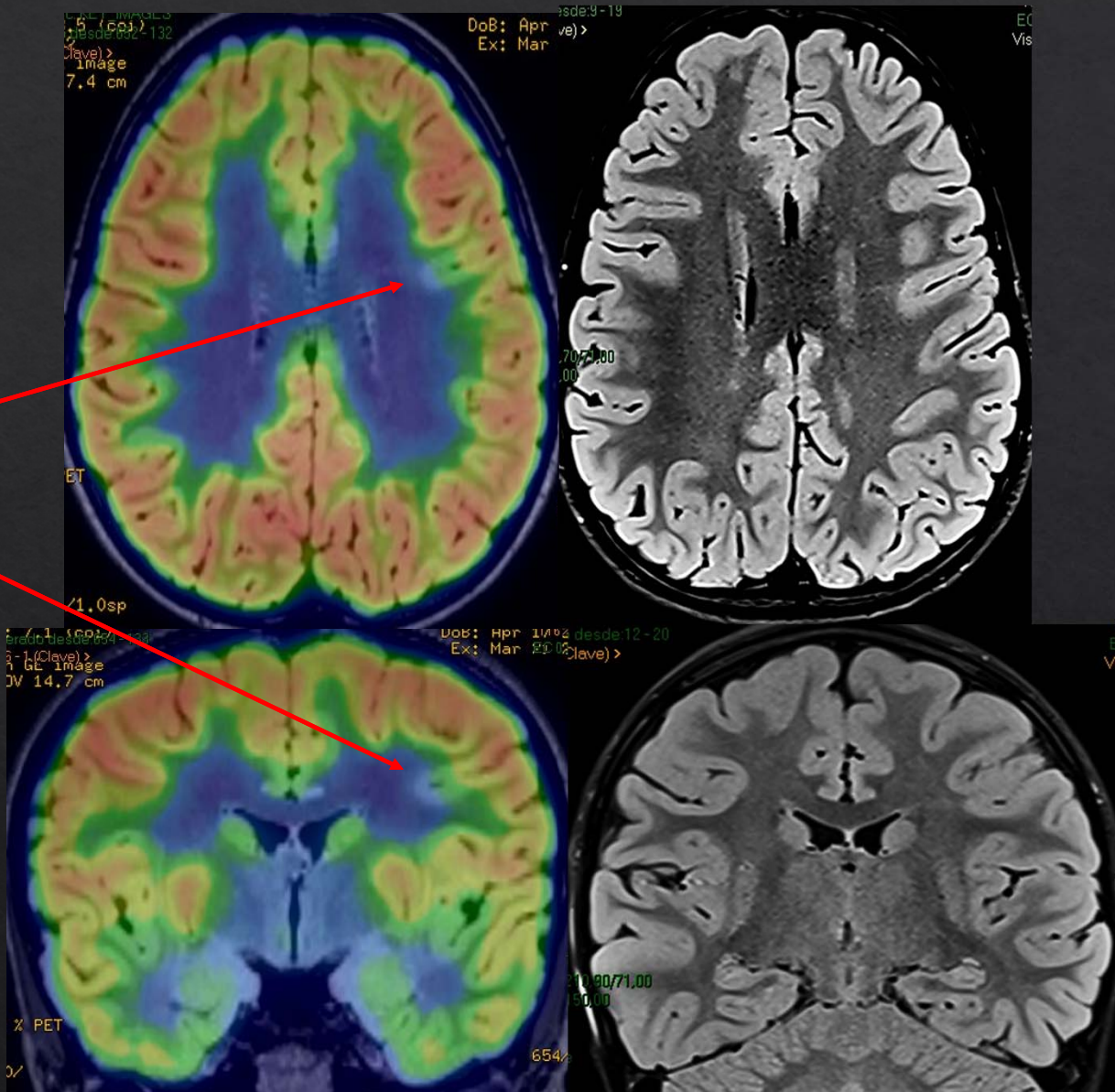
MRI: low Sensitivity
PET (alone) is usually negative



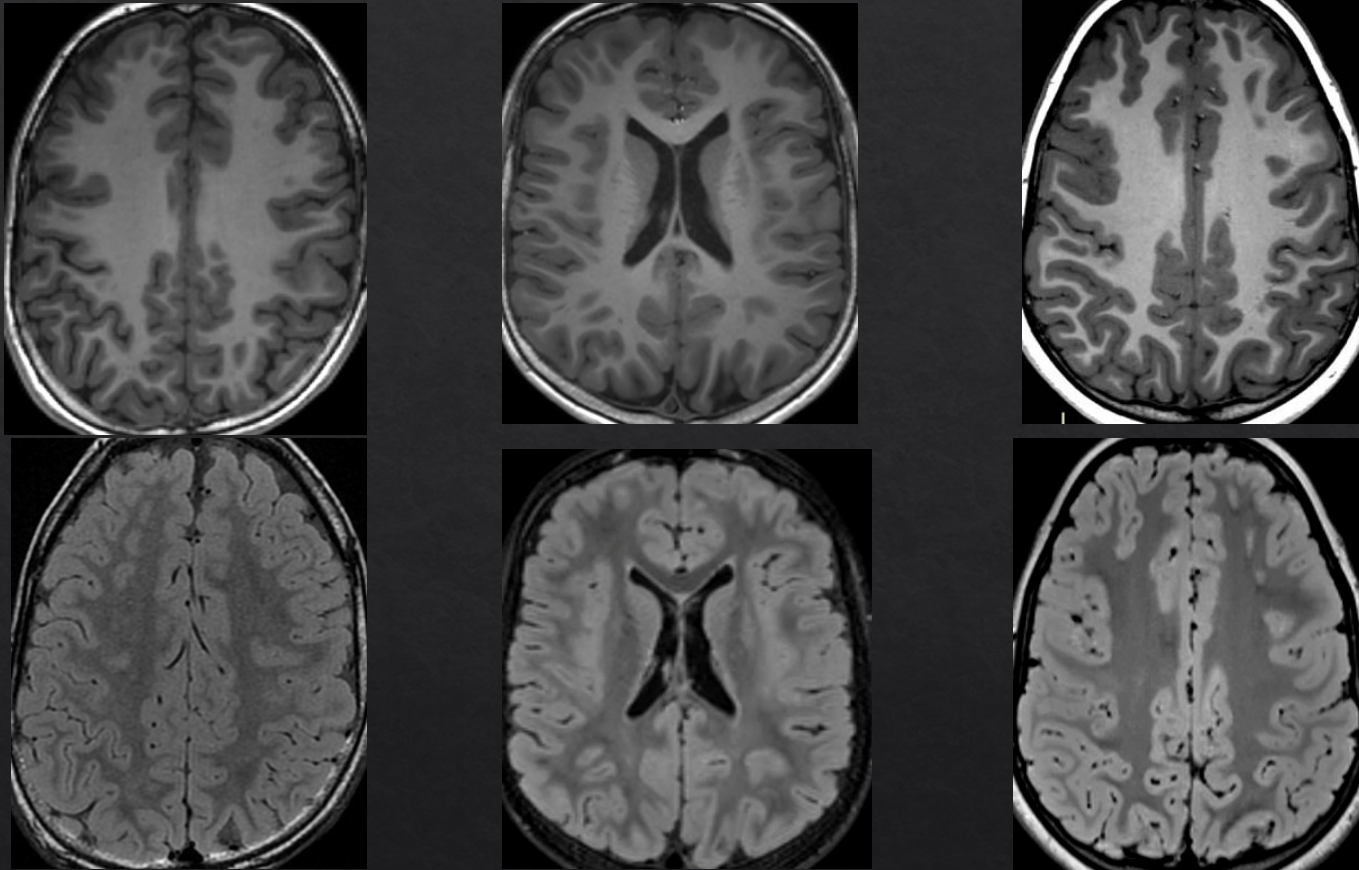
Imaging Protocol:

- High resolution/ contrast MRI
- Fusion PET/MRI

Hipometabolismo
en el fondo del
surco: solo se ve
en la FUSION
PET/RM

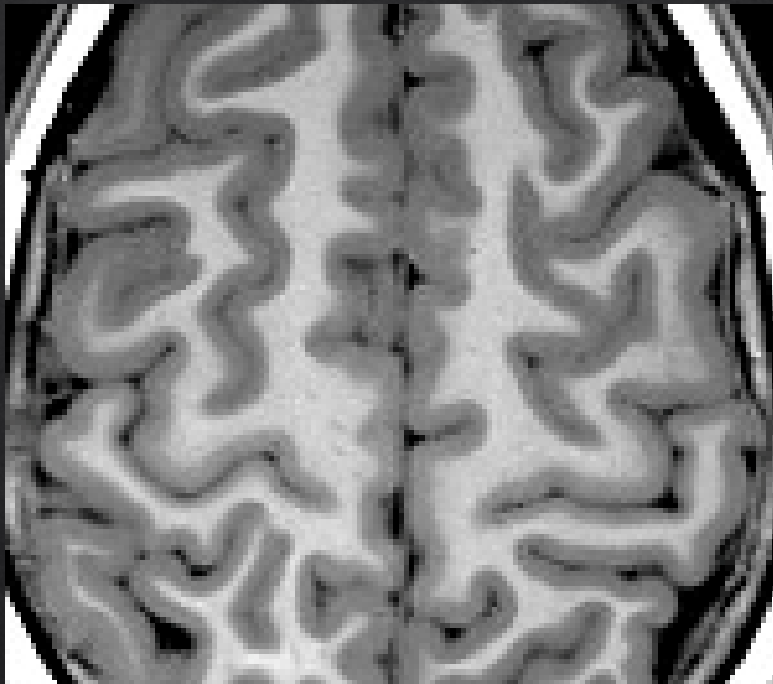


DCF “sutil”



Borrosidad del margen cortical
Señal isointensa con el cortex
NO HAY: hiperintensidad, “transmantle”

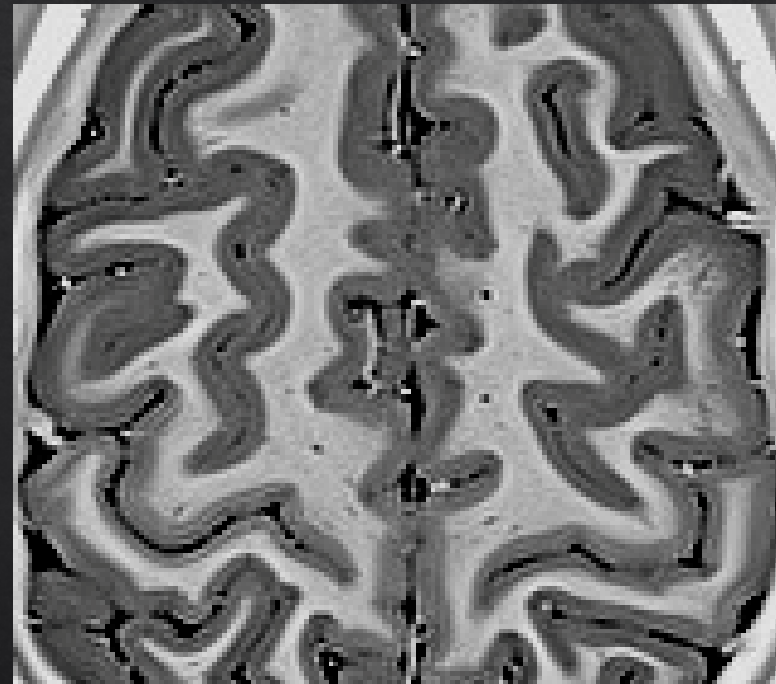
Pulso IR: aumento del contraste



MPRAGE (IR-GE)

3D: 1x1x1mm

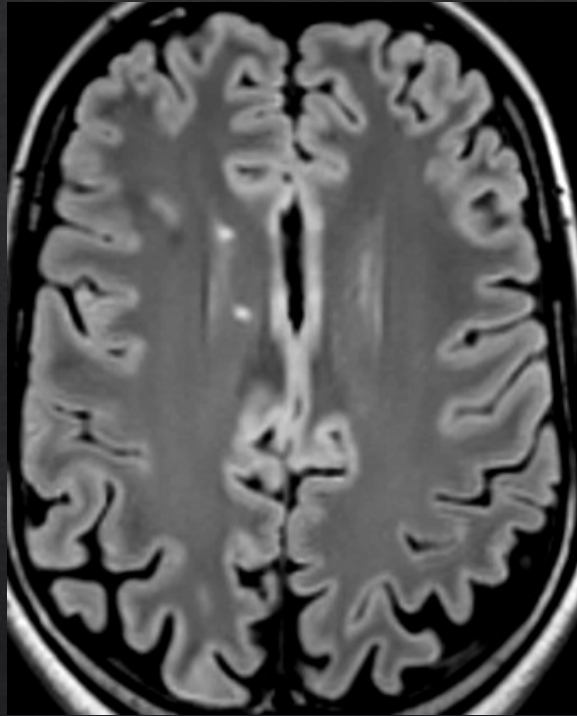
Cobertura completa



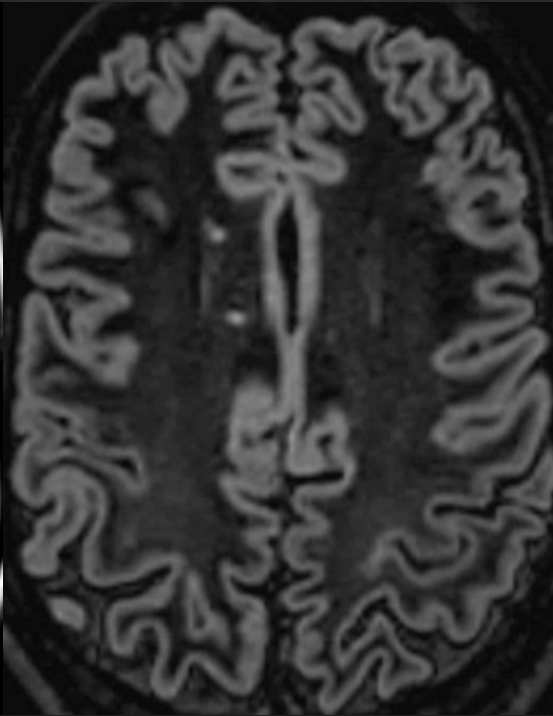
PSIR (IR-T1)

2D: 1x0.3x0.3mm

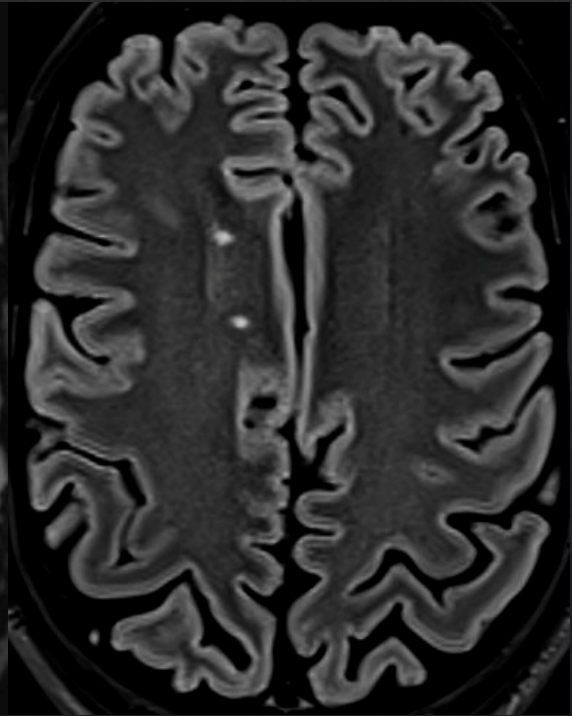
Cobertura limitada



3D-FLAR

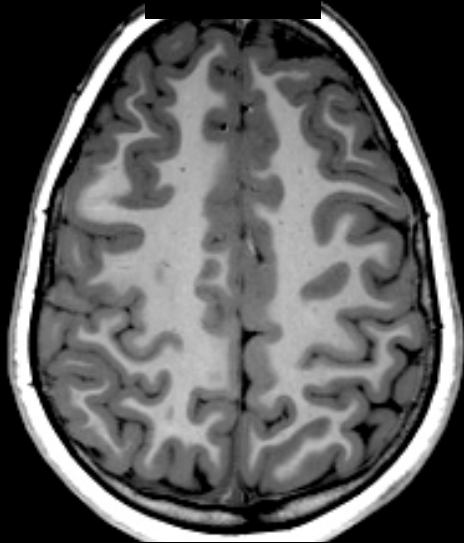


3D-DIR

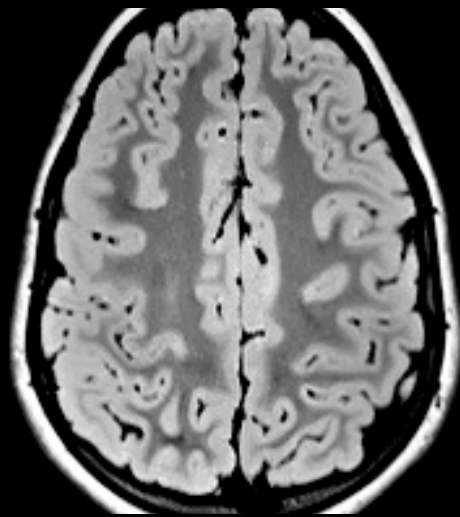

2D-FLAIR AR

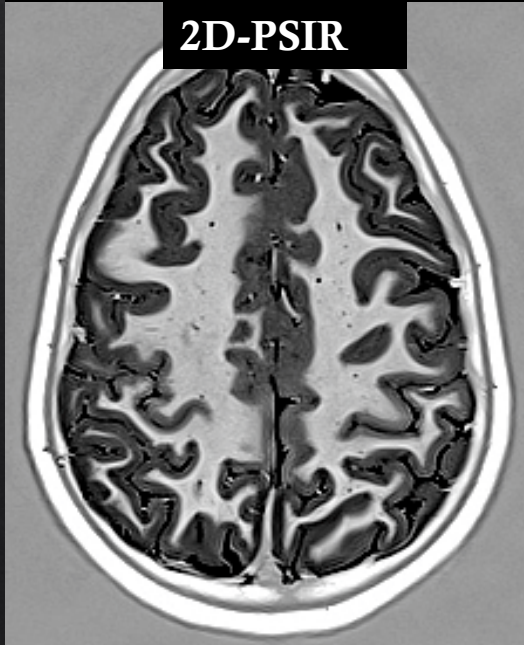
3D-T1



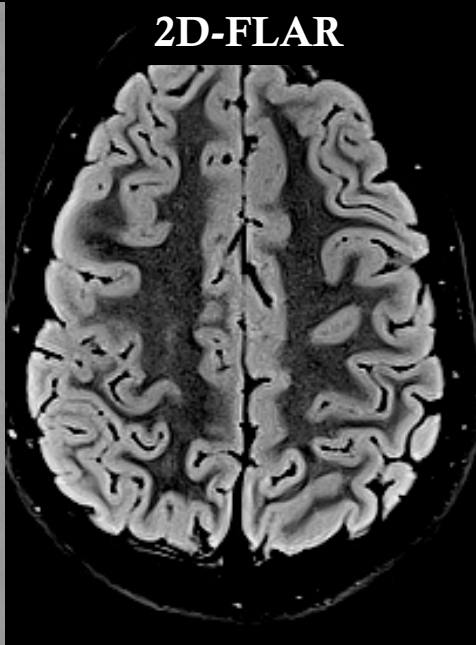3D-FLAR

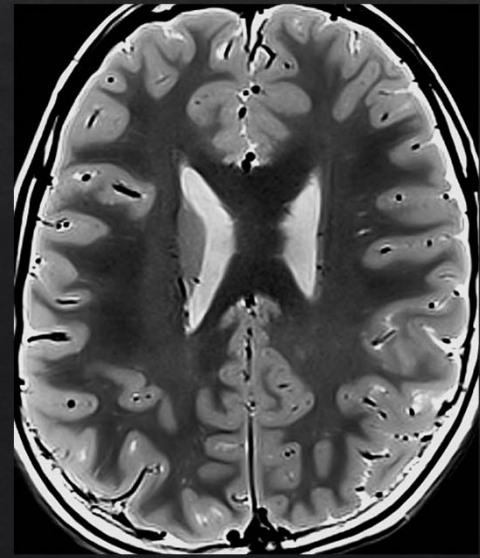
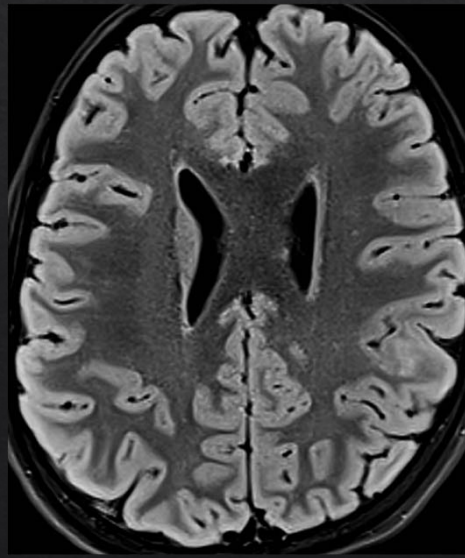
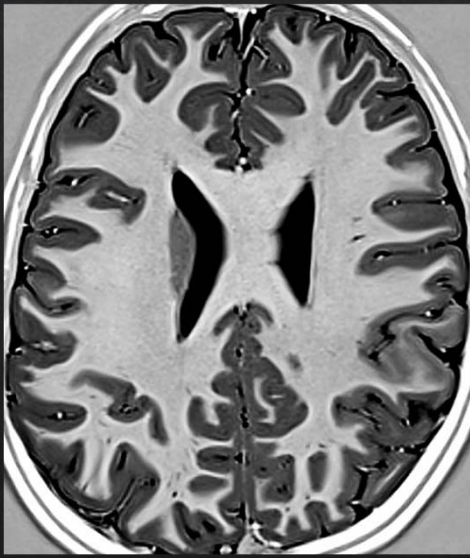
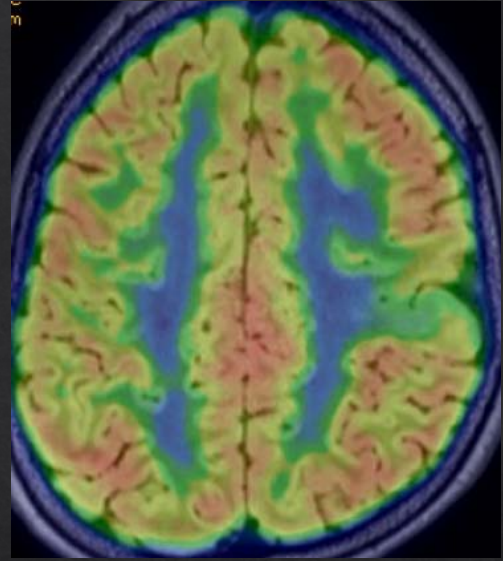
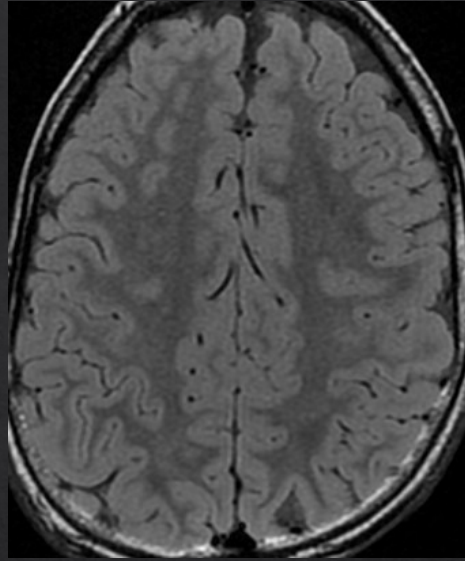
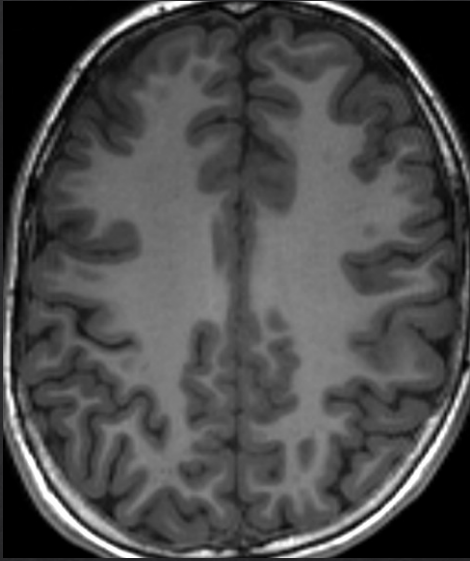


2D-PSIR



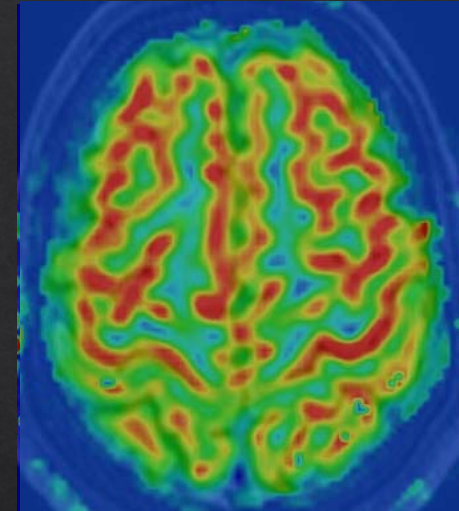
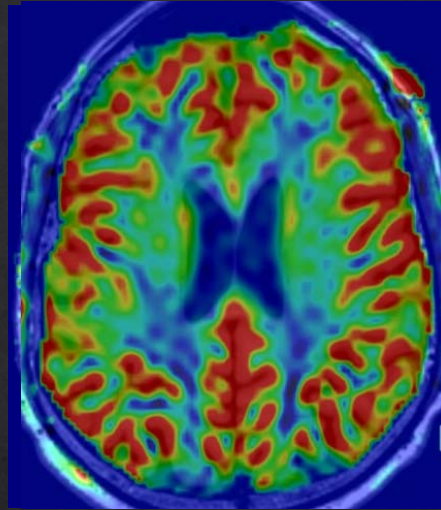
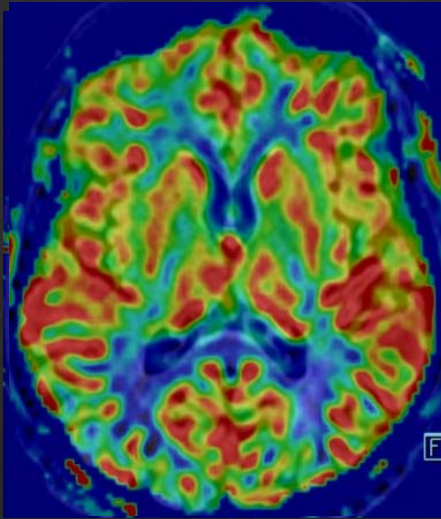
2D-FLAR



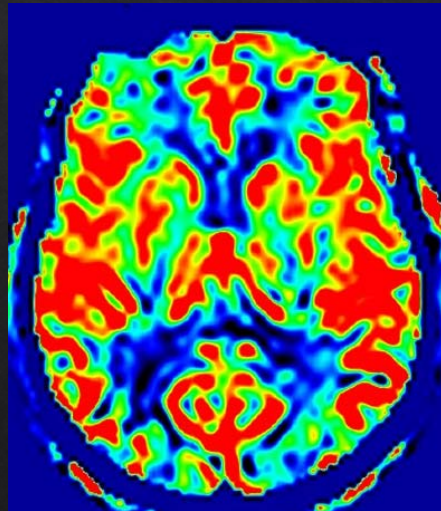


ASL and brain function

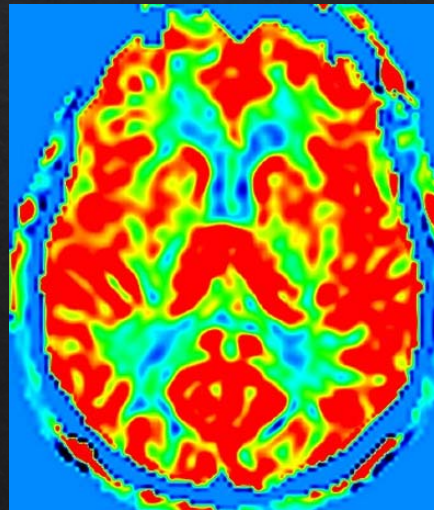
Dynamic
Susceptibility
Contrast : Gd
Intravascular
tracer (CBV)



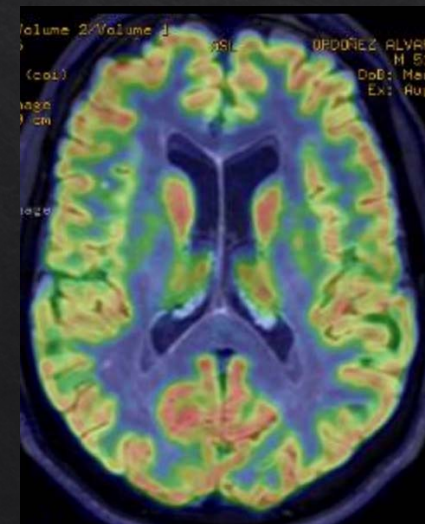
ASL: BLOOD
Diffusible tracer
(tissue perfusion)



ASL short labeling



ASL long labeling



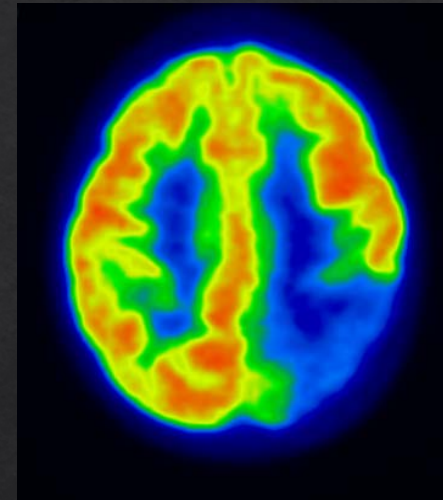
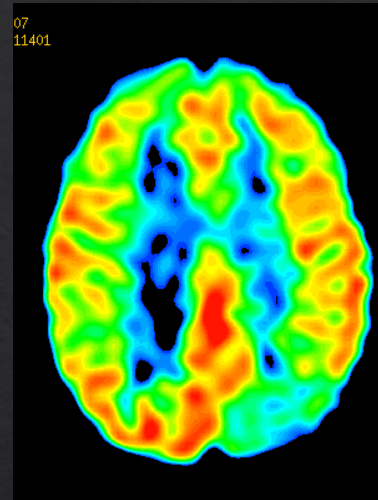
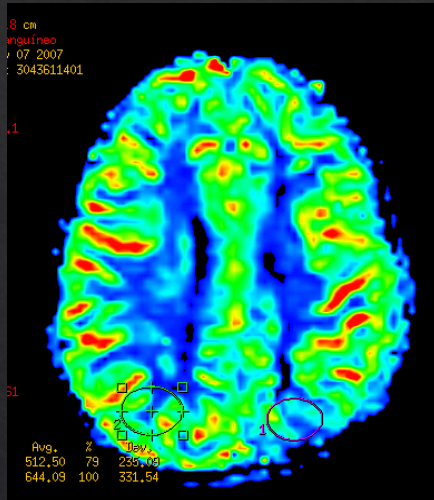
FDG-PET

Brain Function: perfusion/metabolism coupling

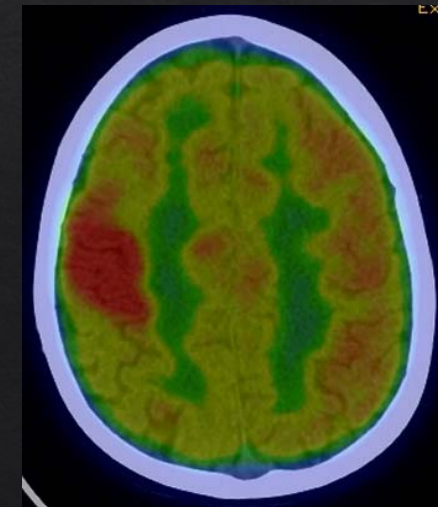
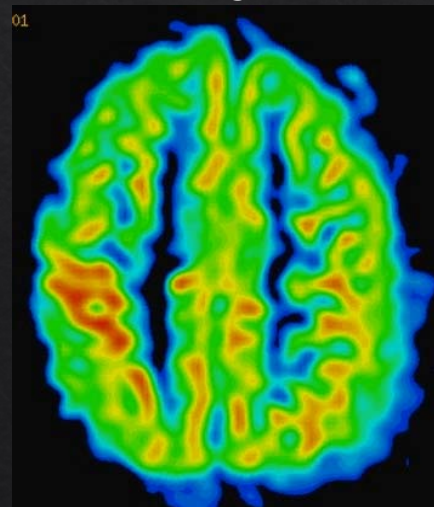
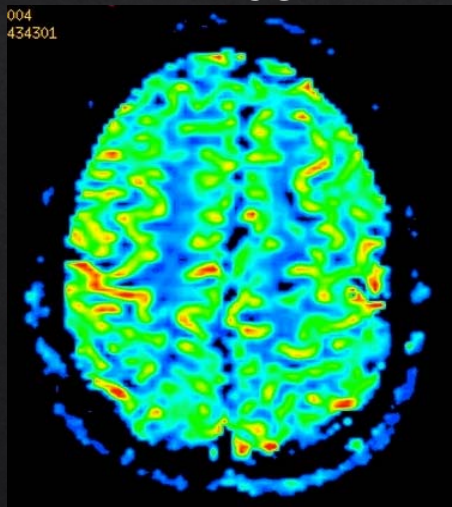
SENSITIVITY

DSC < ASL

ASL < PET

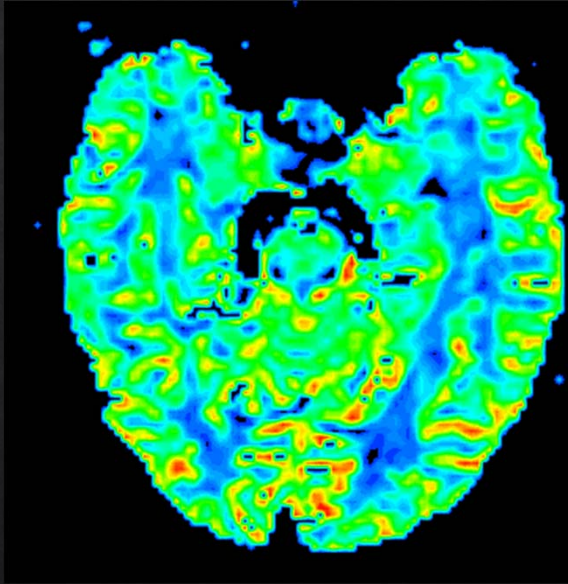
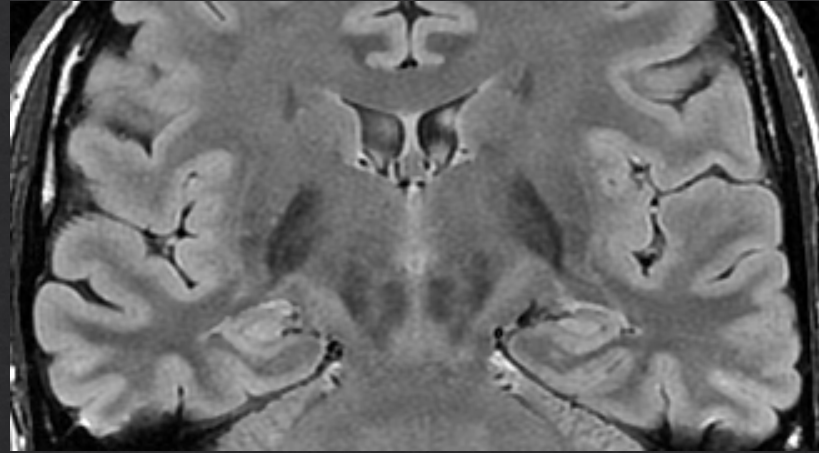
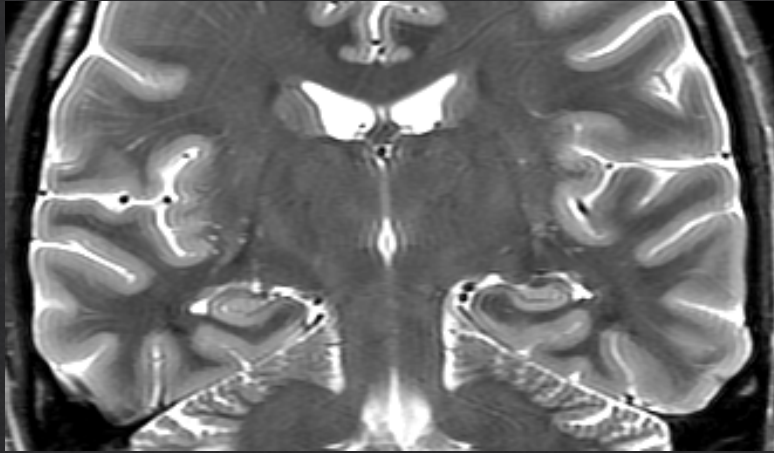


INTERICTAL
FUNCTION

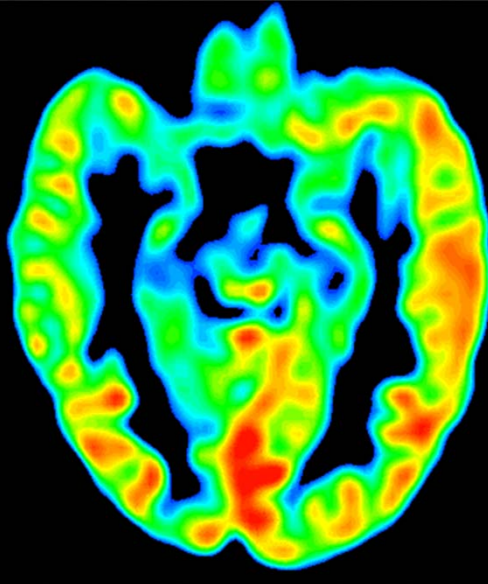


ICTAL
FUNCTION

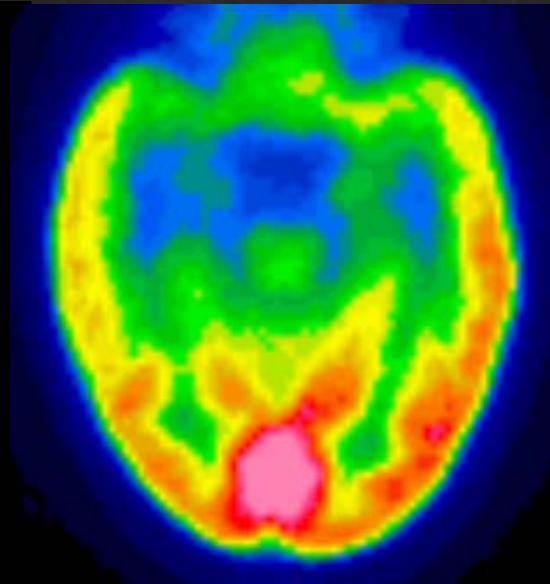




DSC

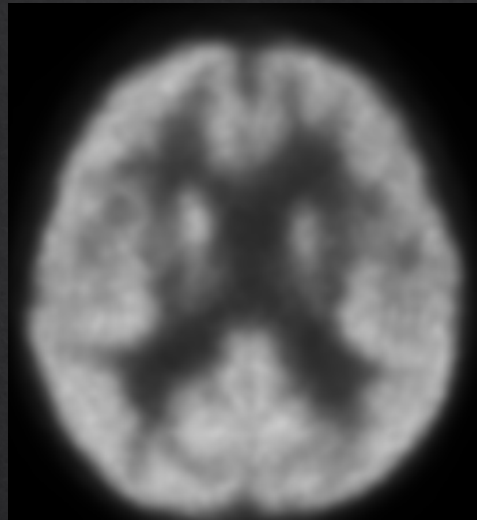


ASL

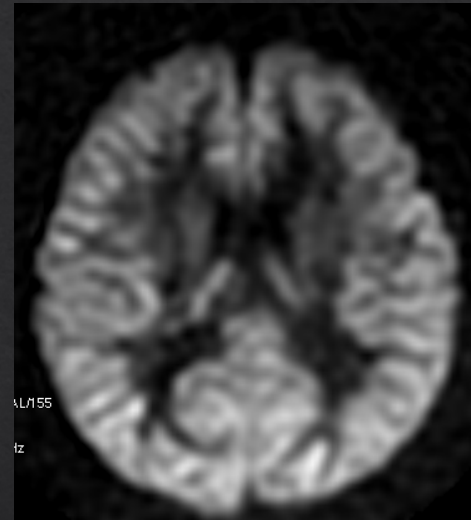


PET

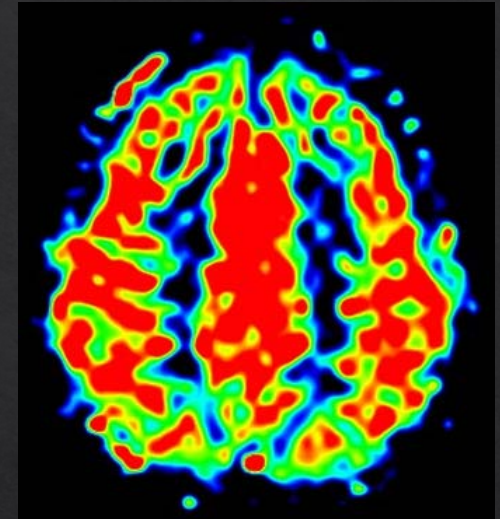
PET:
Fix Resolution
3D isotropic
3-5 mm
High sensitivity



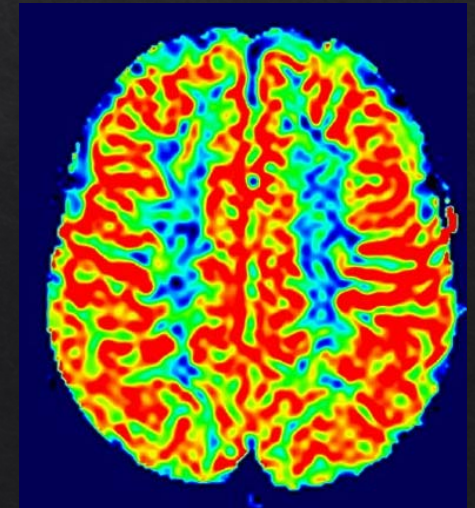
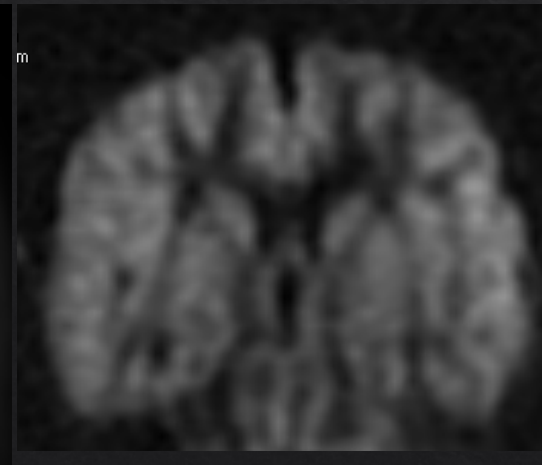
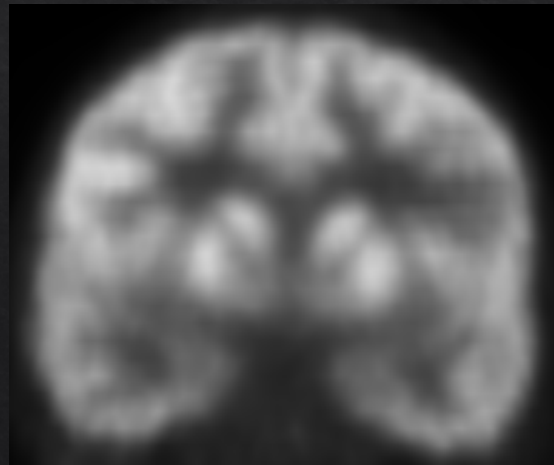
PET

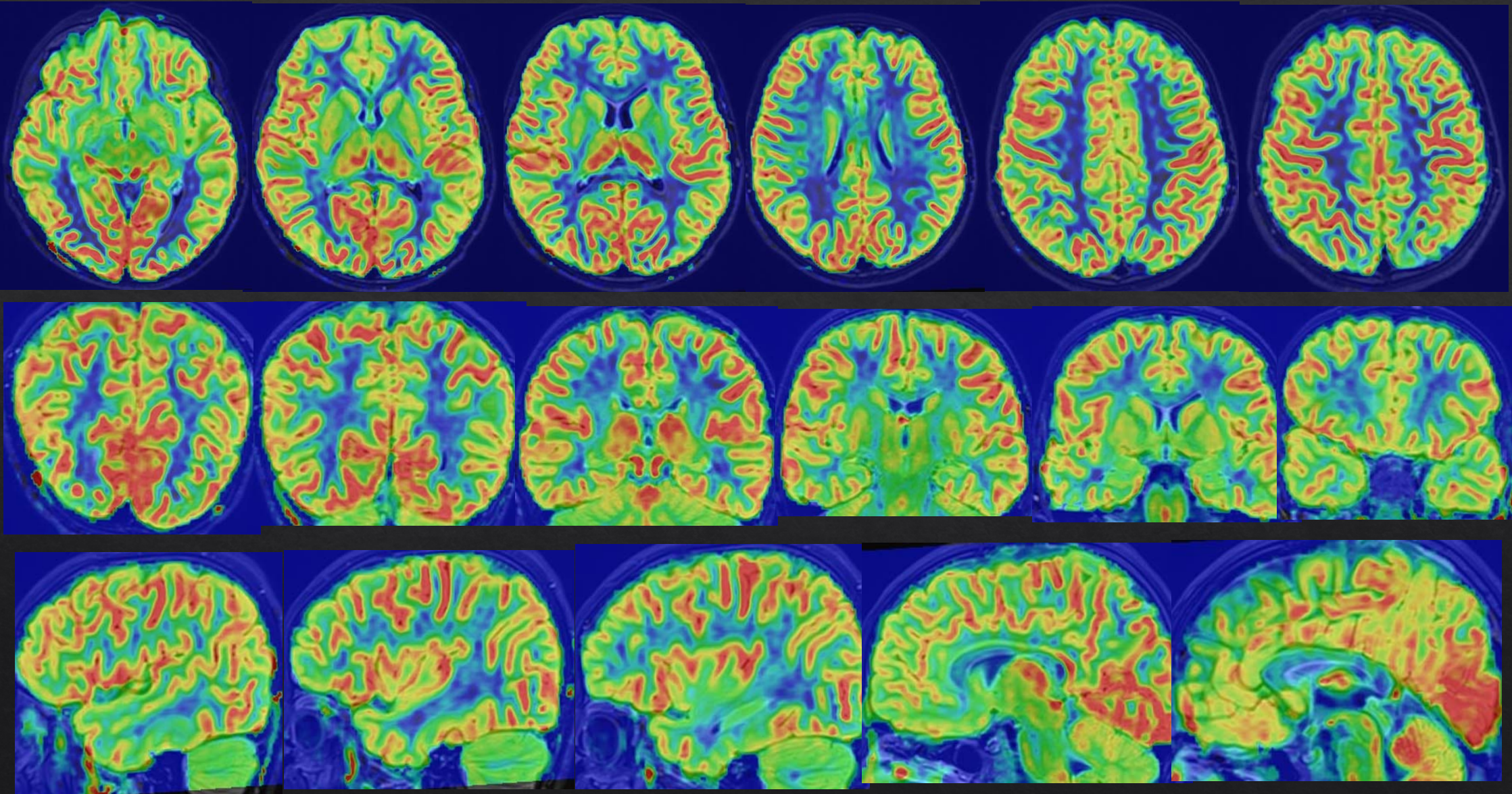


High Resolution ASL



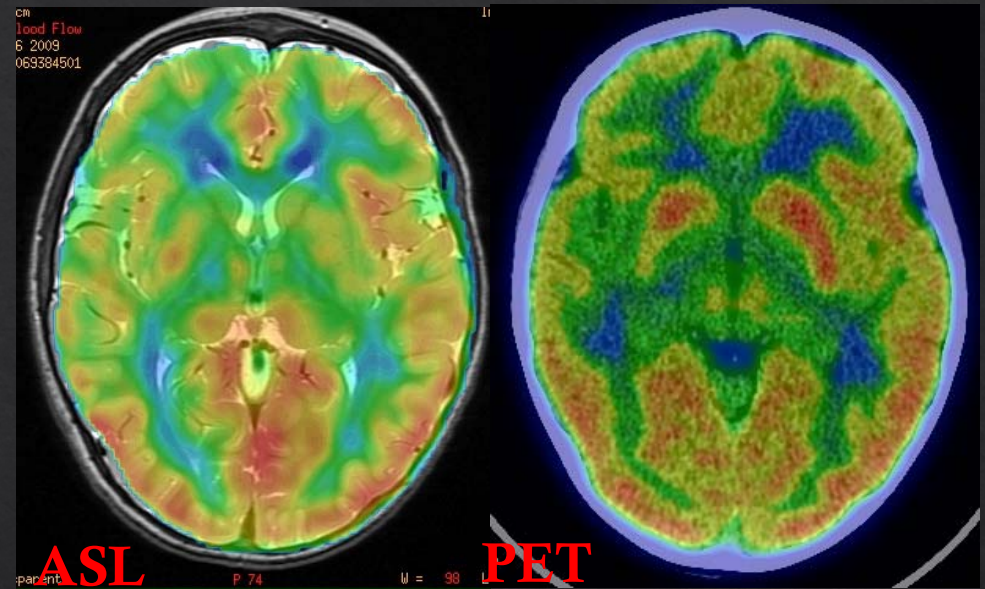
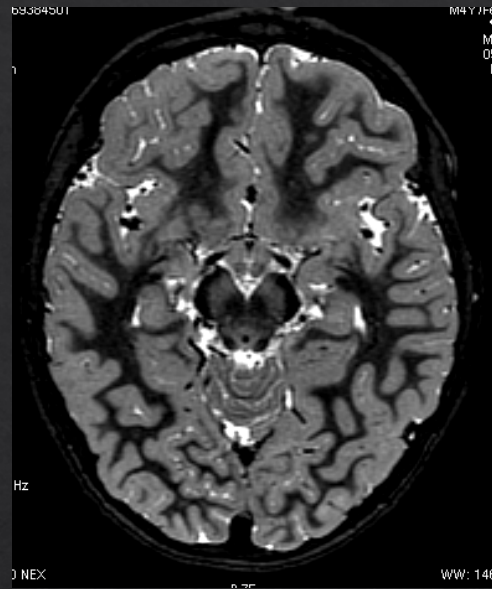
3D-PCASL:
Lower sensitivity
Resolution can be
adjusted:
SNR
Acq time
3D isotropic
Up to 1.5mm





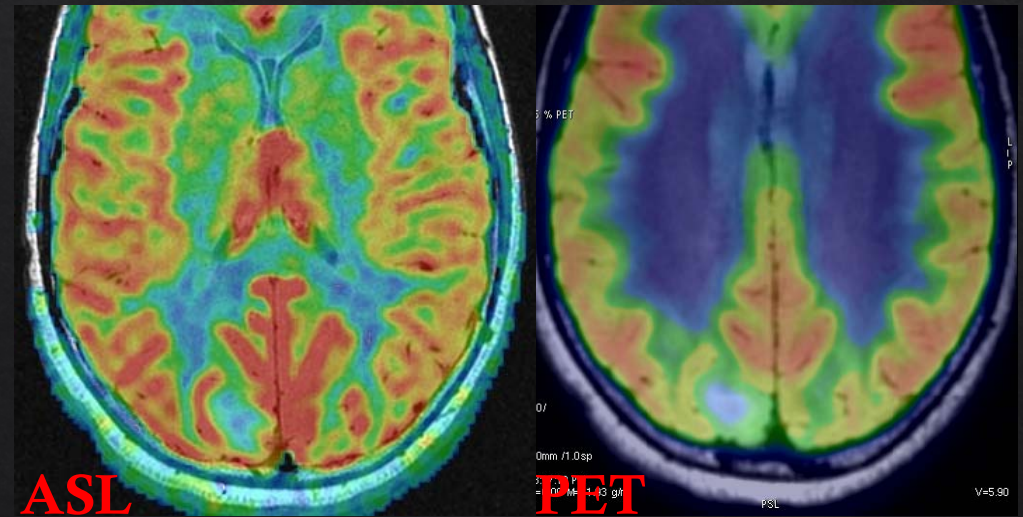
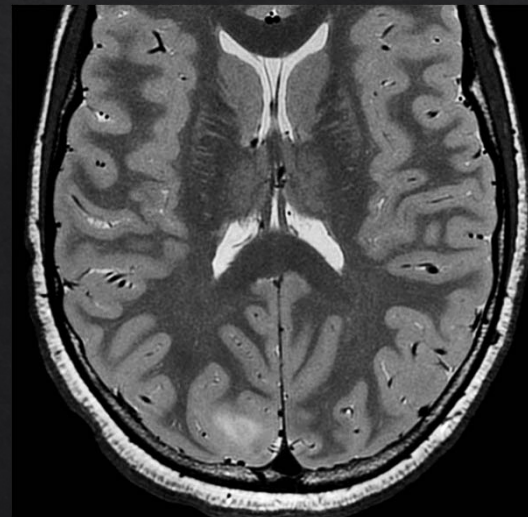
Big lesión (type I FCD)

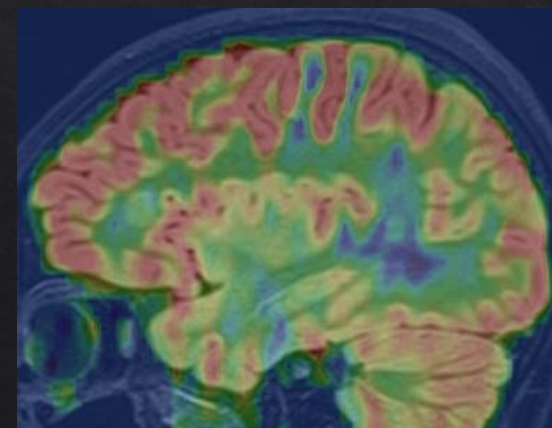
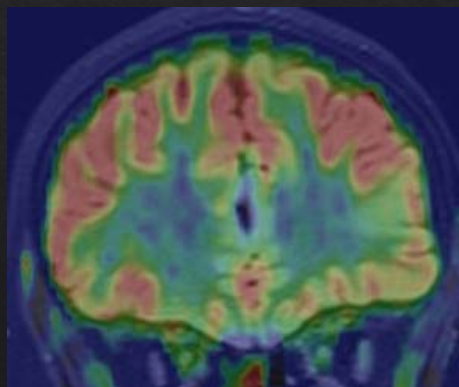
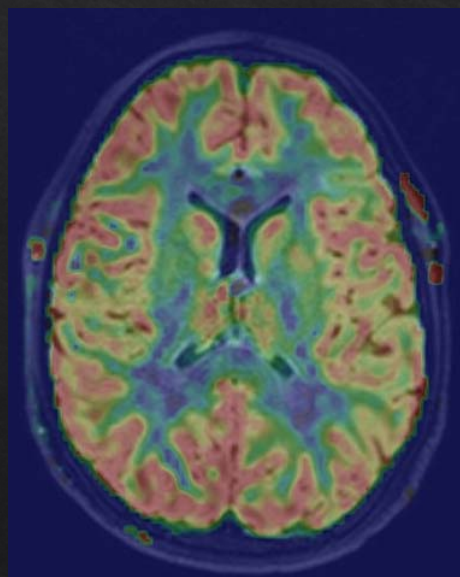
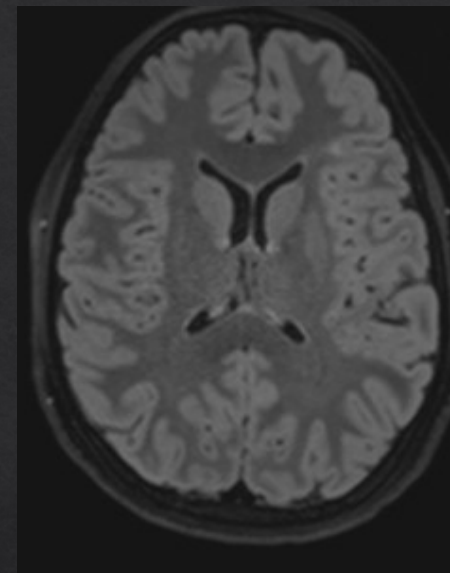
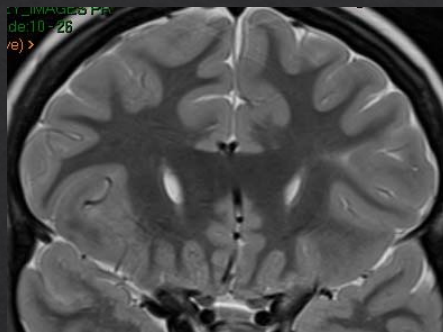
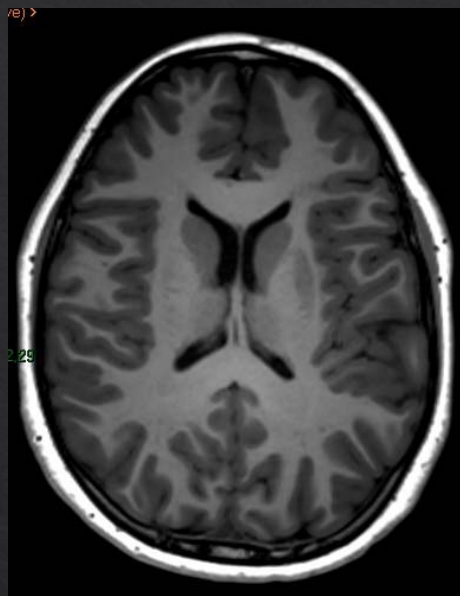
Low resolution ASL

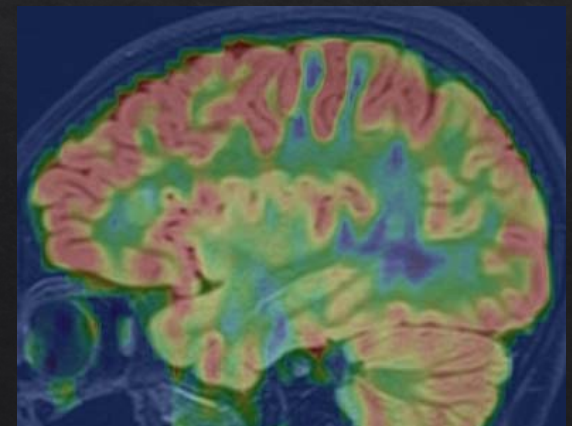
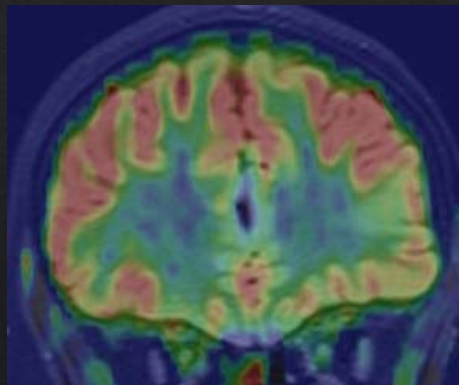
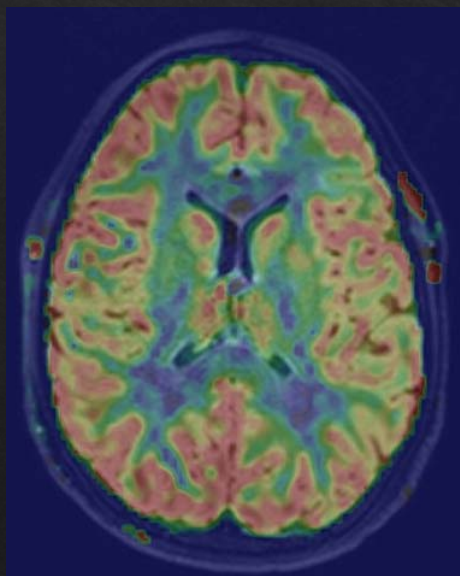
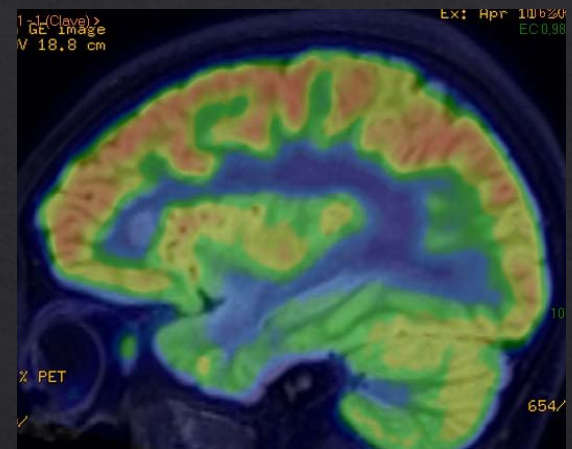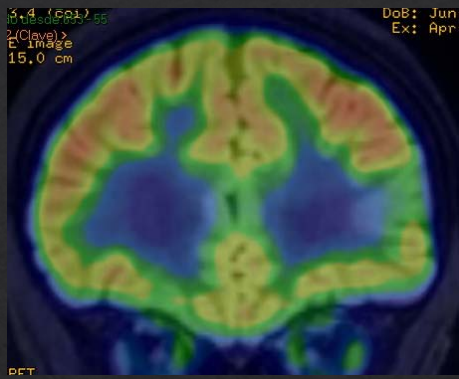
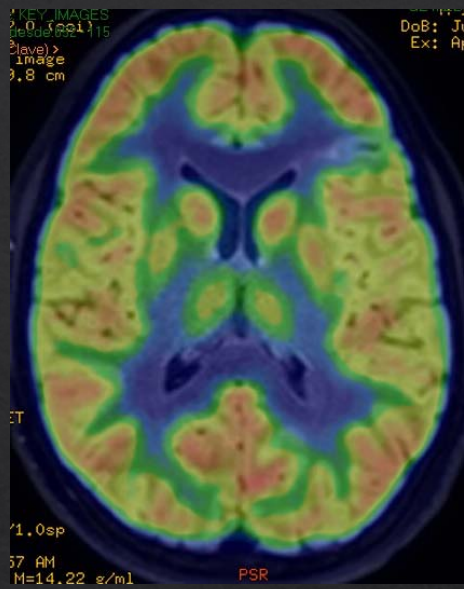


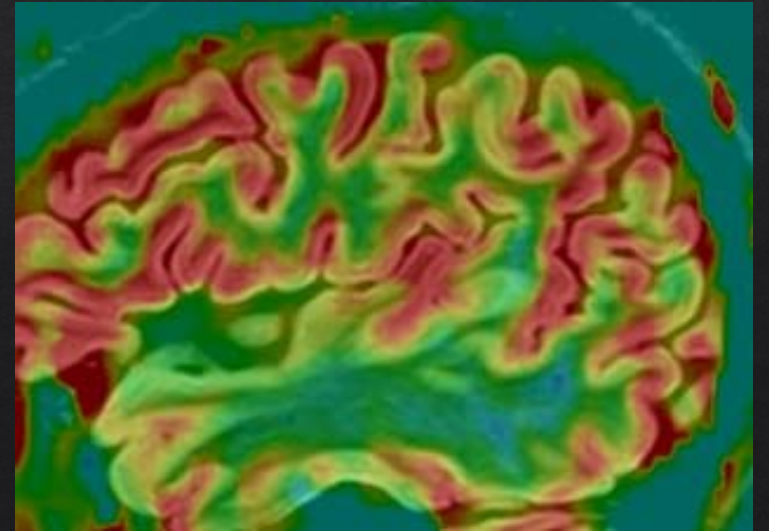
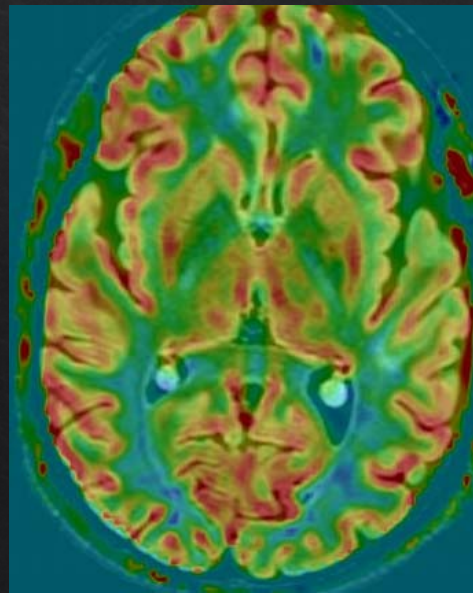
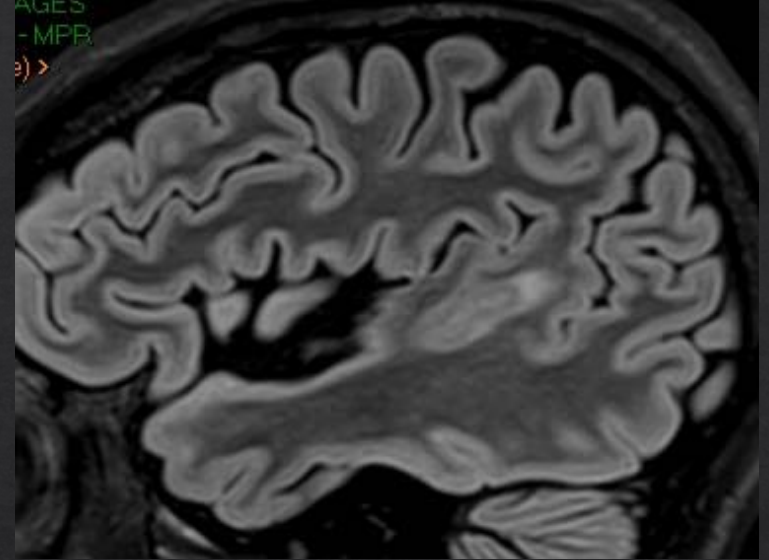
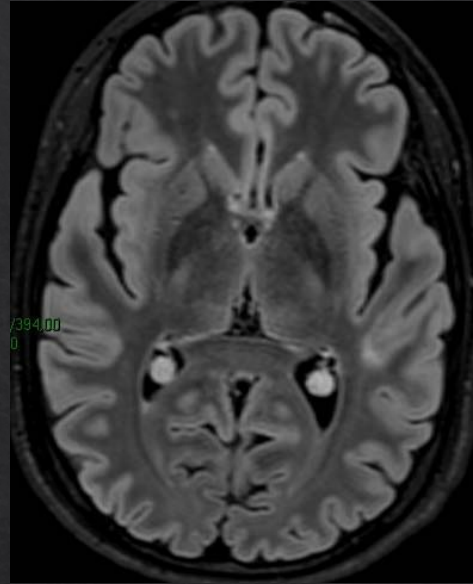
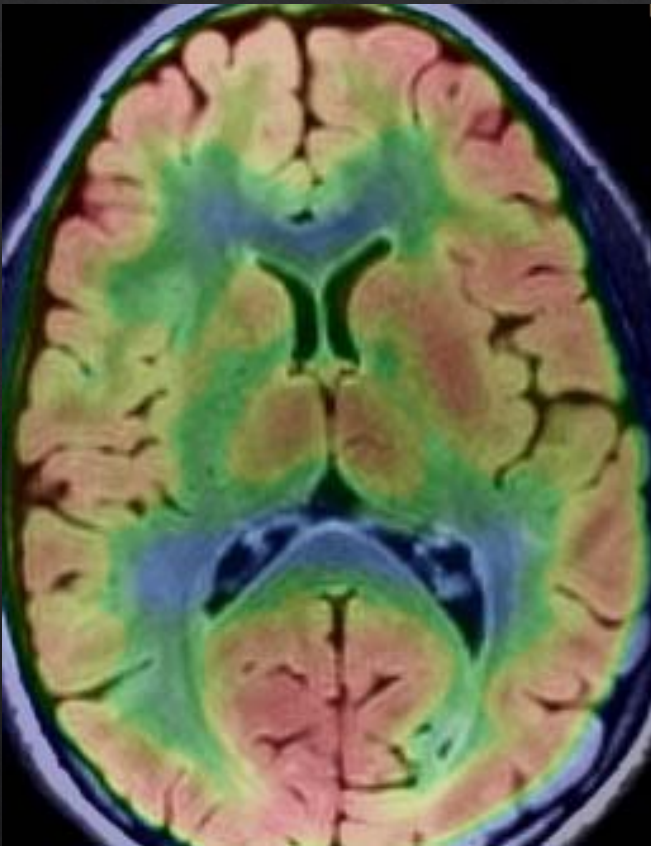
Small lesión (type II FCD)

High resolution ASL

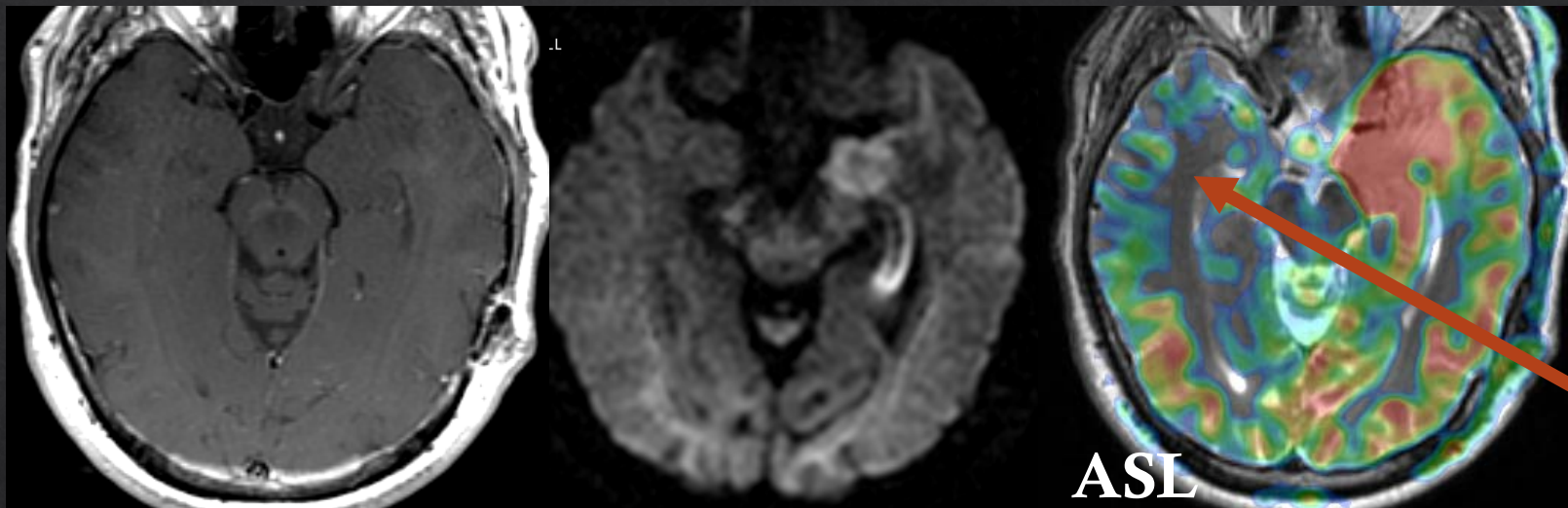




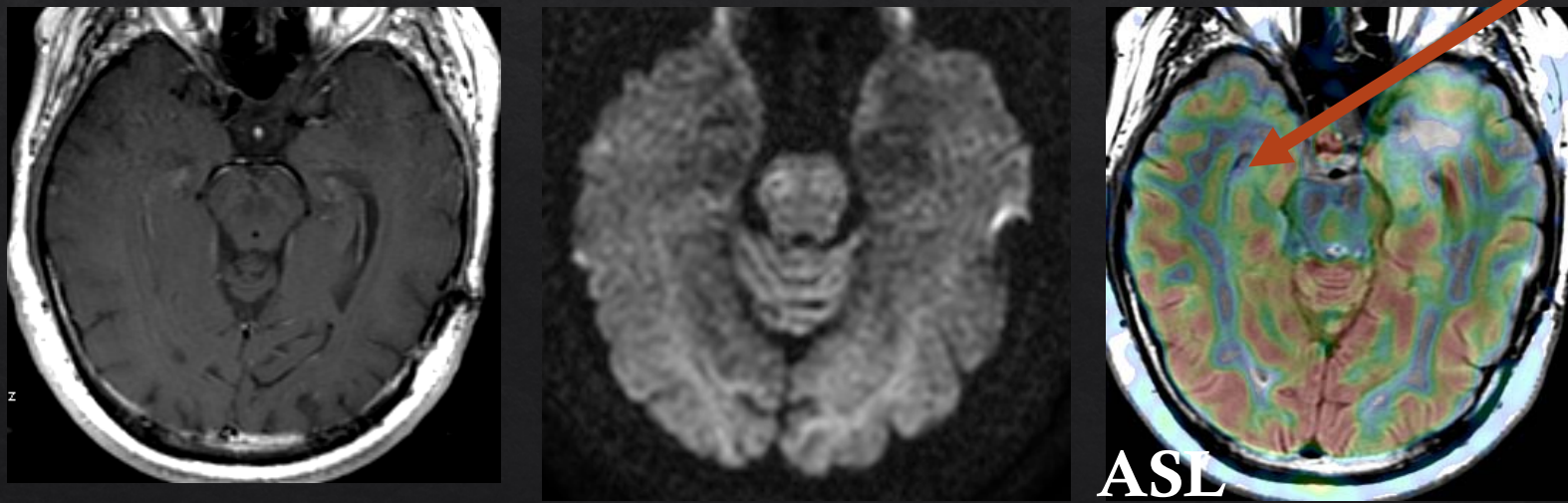




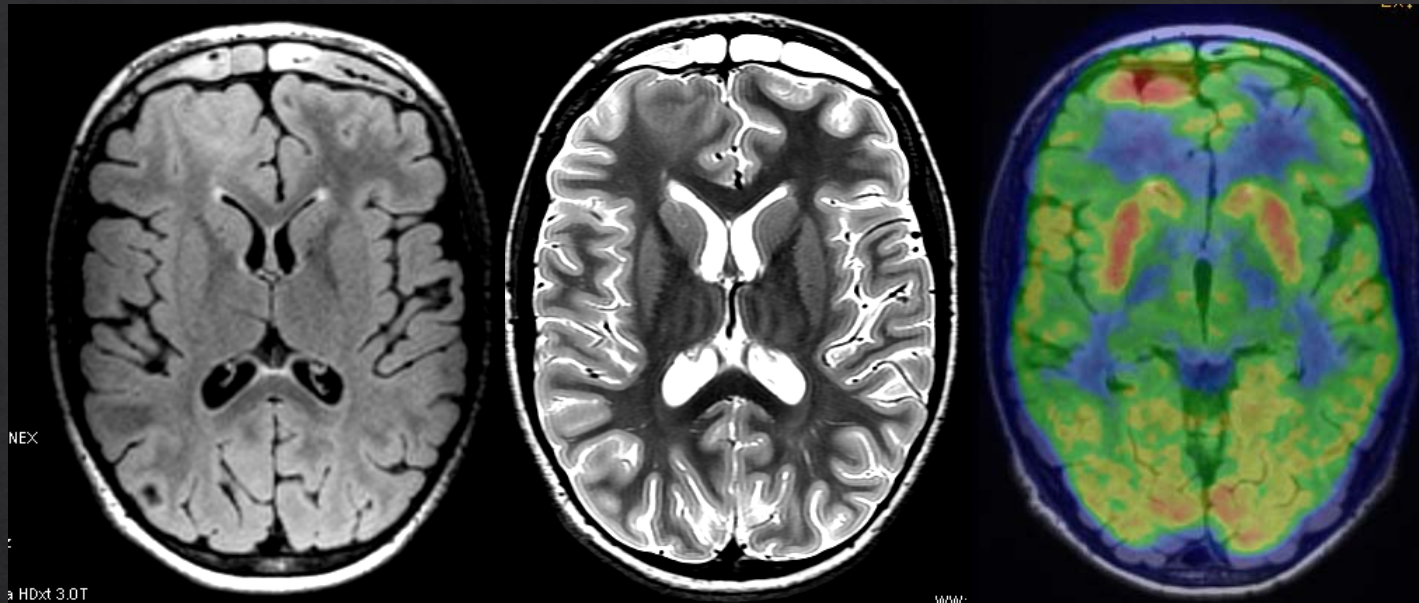
Status epilepticus



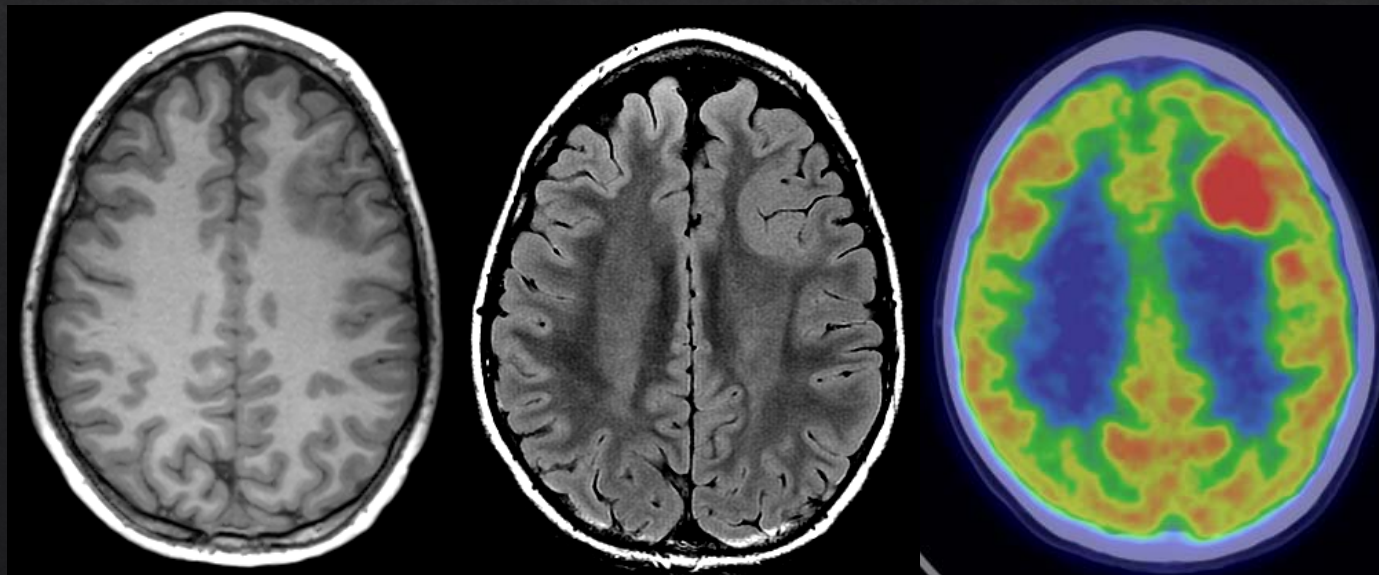
Reactive changes

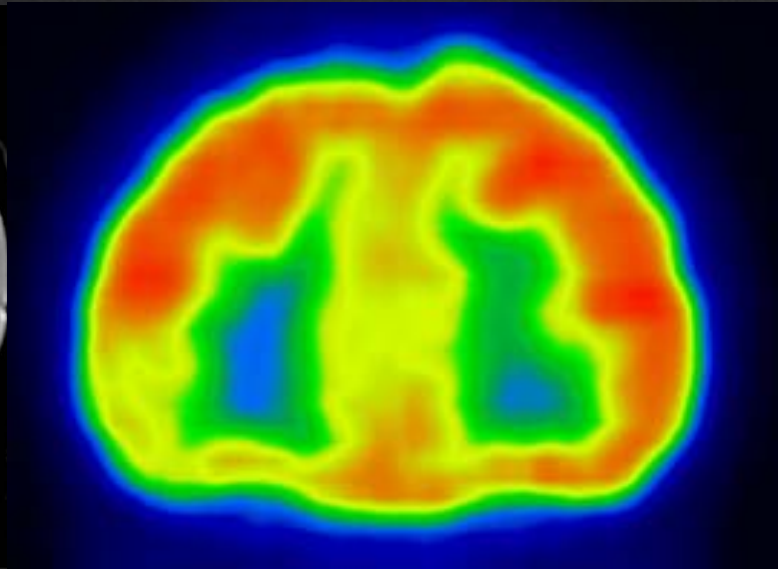
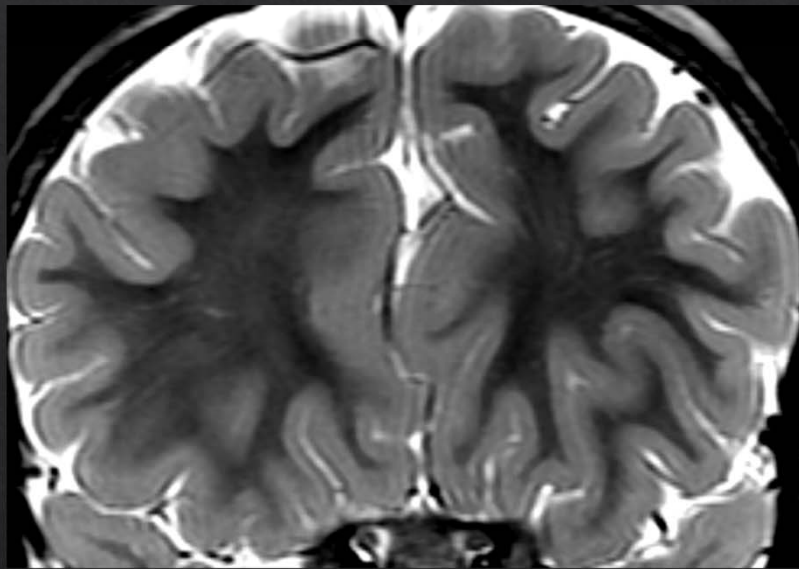


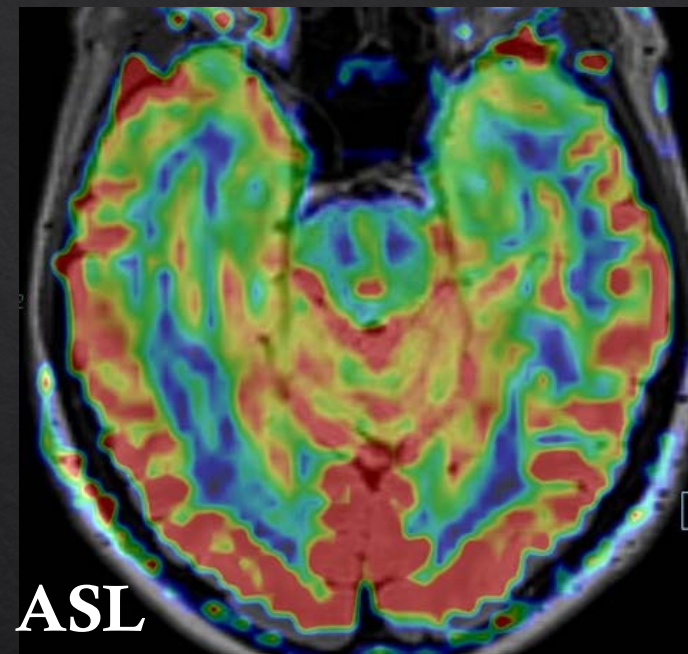
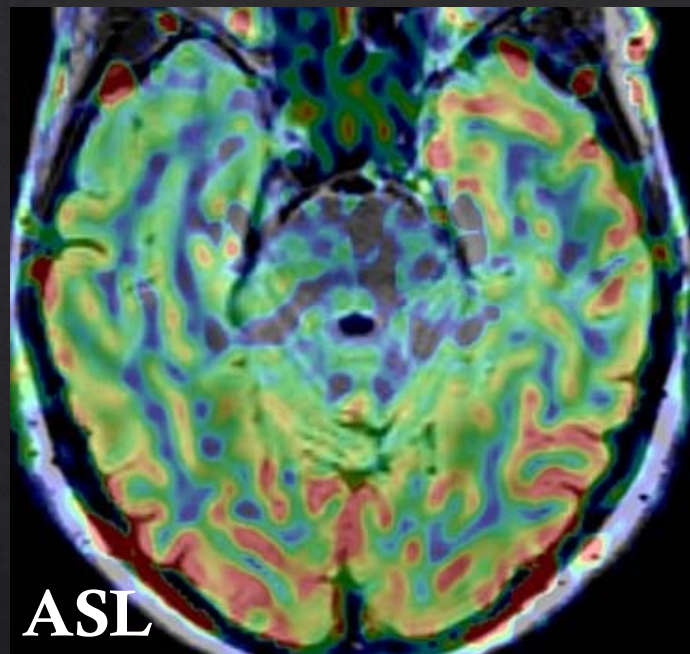
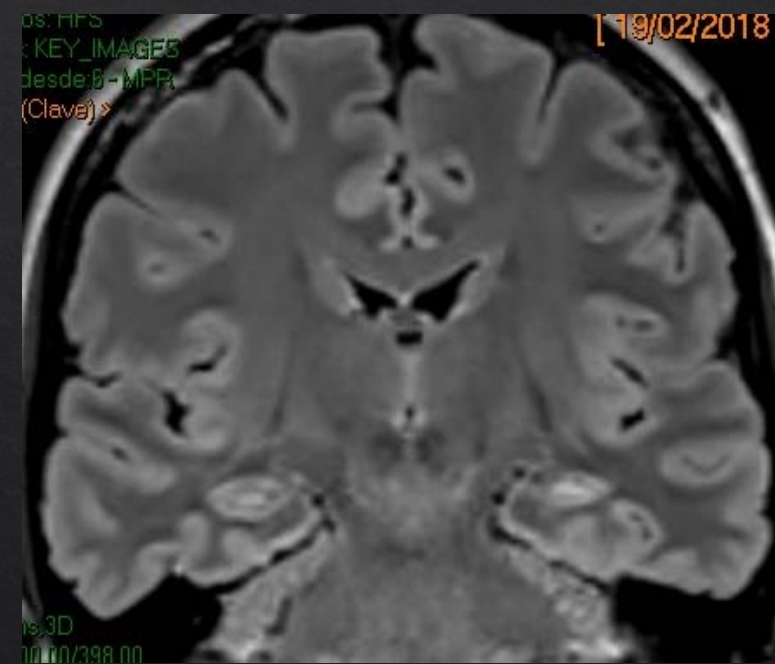
FCD with
status
epilepticus:
Focal High
activity and
global low
activity



FCD with
continuous
activity:
Focal High
activity

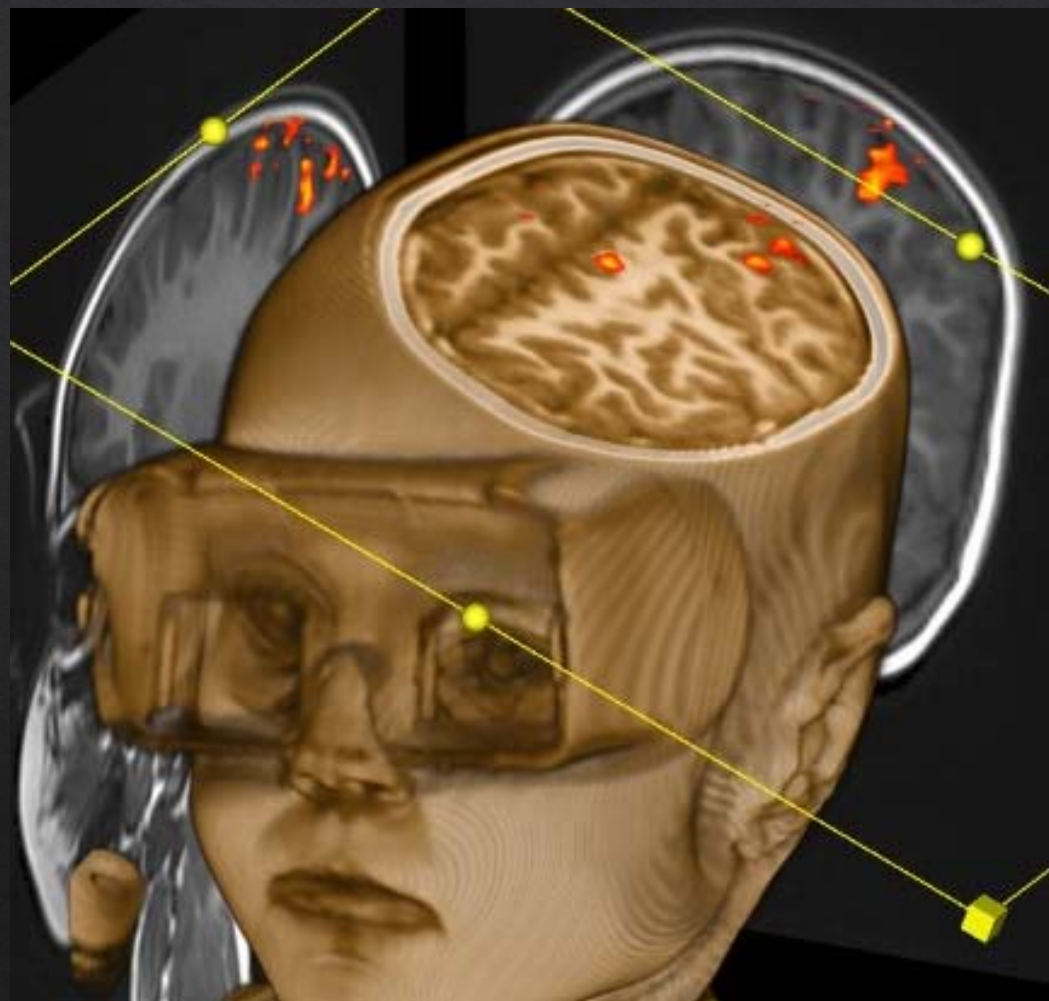
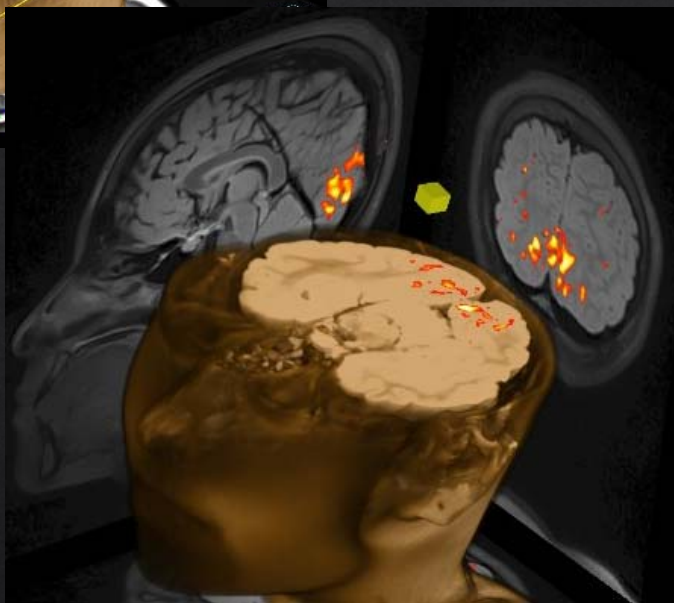
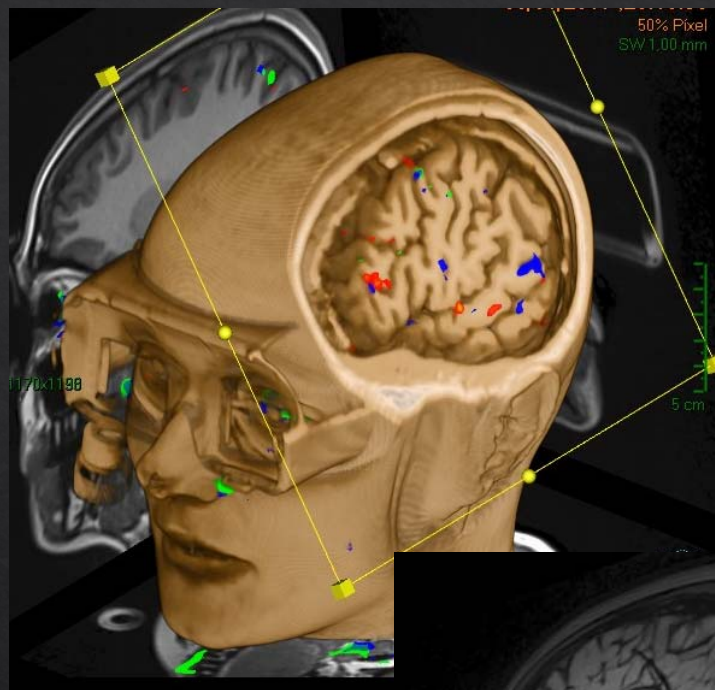


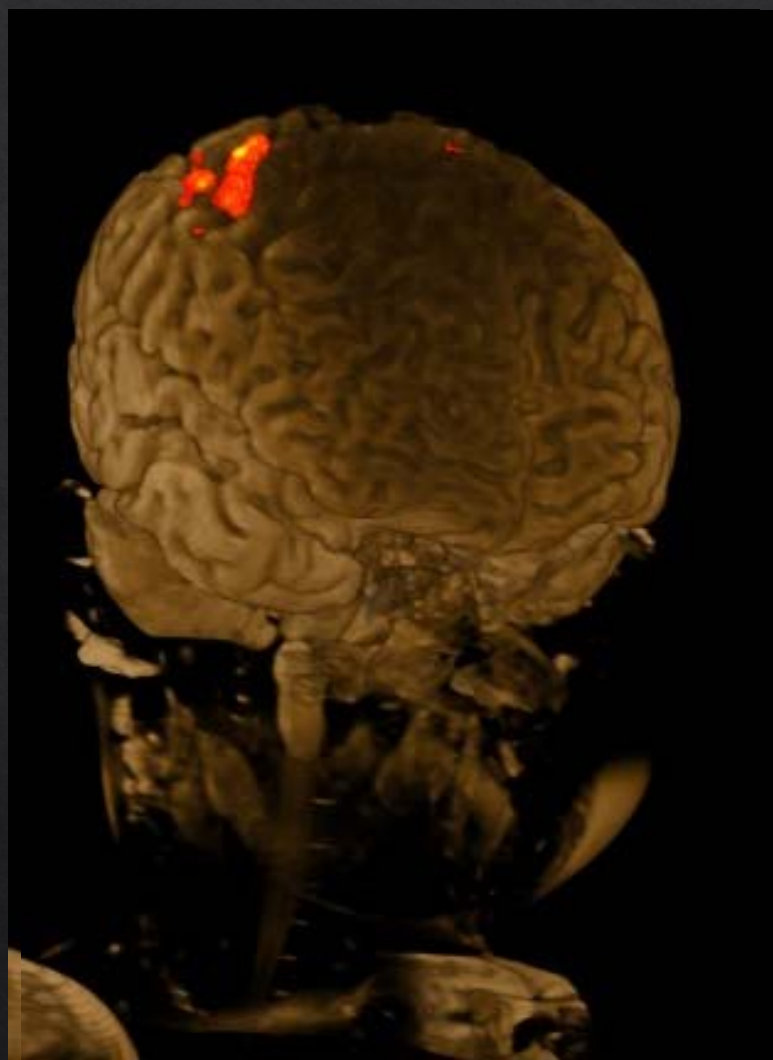




RMf y Tractografía en la cirugía de la epilepsia

- ◇ Estudio prequirúrgico: multidisciplinar
 - ◇ Extensión: RM estructural (estudio selectivo)
 - ◇ Corteza “elocuente”: RMf (motor, lenguaje)
 - ◇ Conexiones: Tractografía (TC-Espinal, F-Arqueado, Radiaciones)
- ◇ RMf: alta resolución (3T)
 - ◇ Bloques: tareas (> 4 años)
 - ◇ Resting: despierto, sedación
- ◇ Tractografía: múltiples direcciones
 - ◇ No requiere colaboración
 - ◇ Más robusta que la RMf





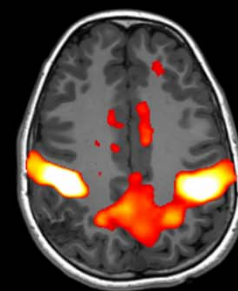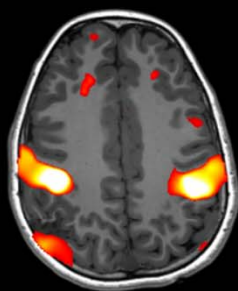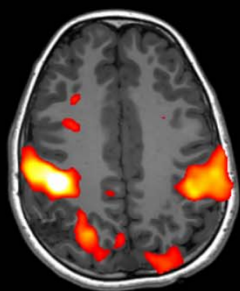
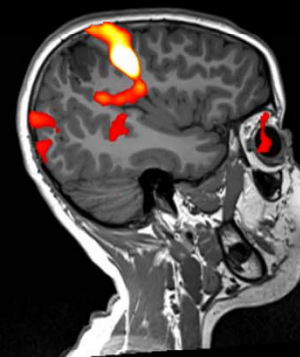
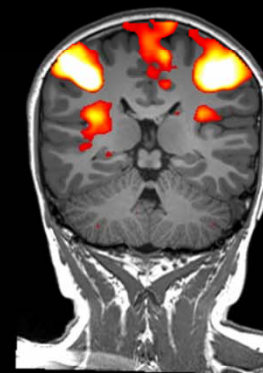
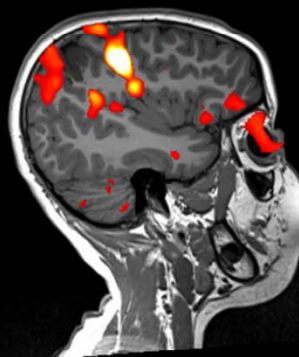
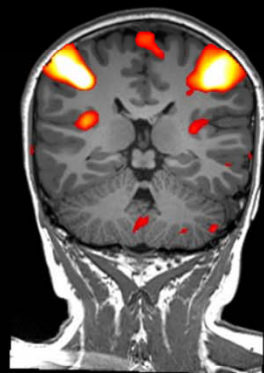
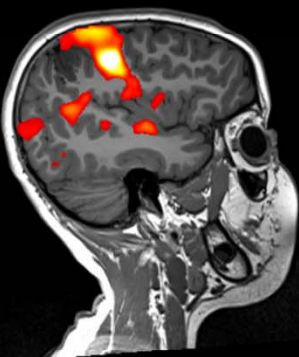
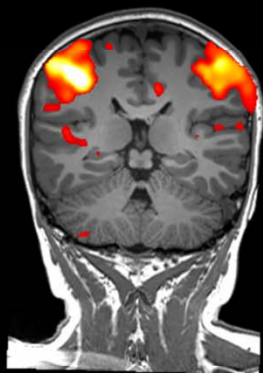
“Resting State” fMRI: Ventajas

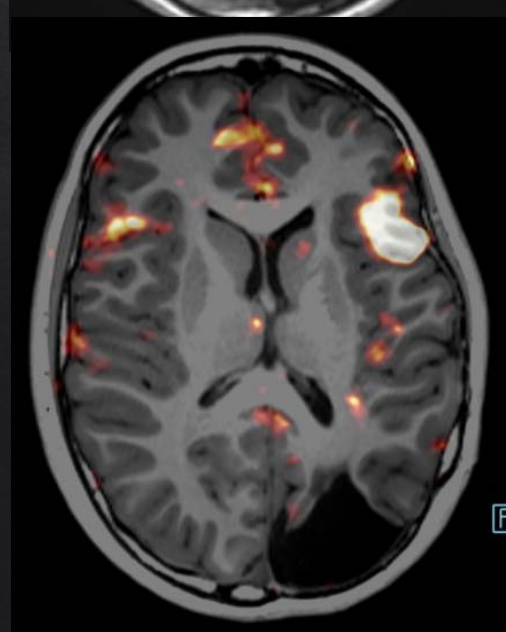
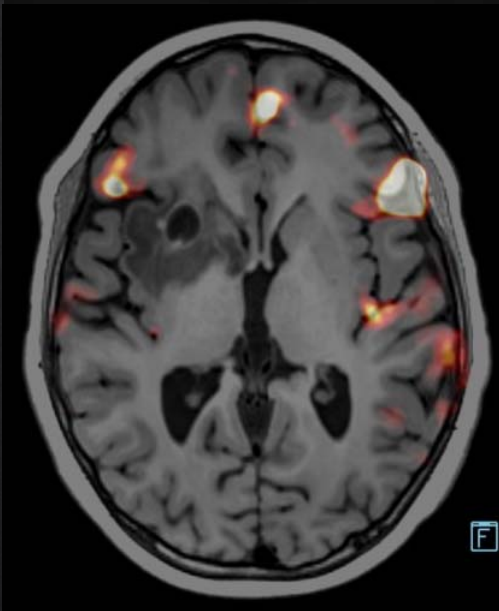
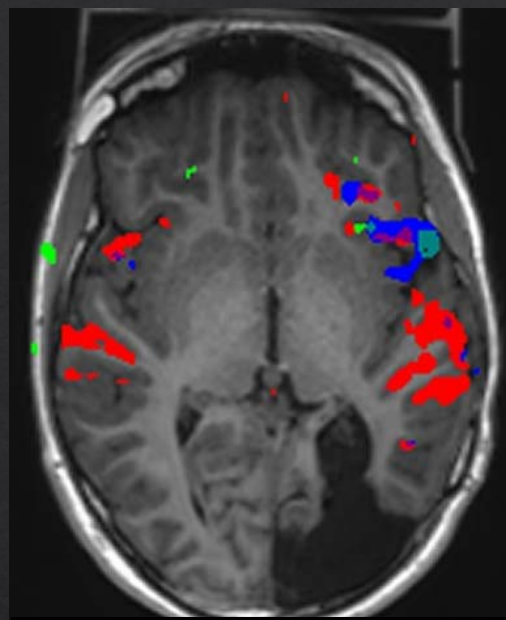
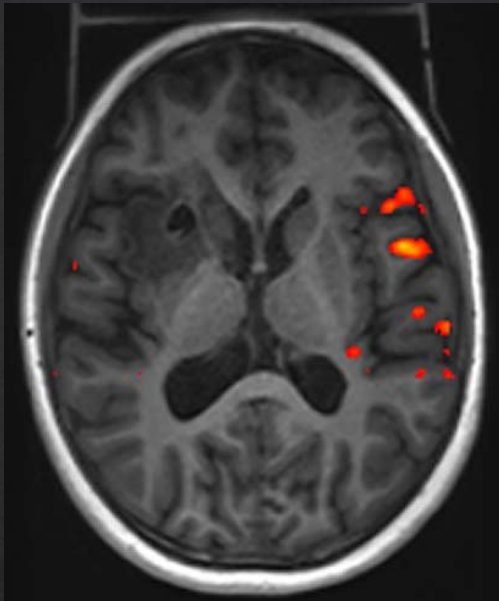
- ◇ No hay tarea
 - ◇ No necesita colaboración
 - ◇ Niños, deterioro cognitivo, sedación
- ◇ Permite estudiar redes de forma más precisa (CUANTIFICACIÓN)
 - ◇ Conectividad
 - ◇ Topología (EFICIENCIA): Teoría de grafos
- ◇ Principales DESVENTAJAS
 - ◇ Postproceso complejo
 - ◇ Poca experiencia

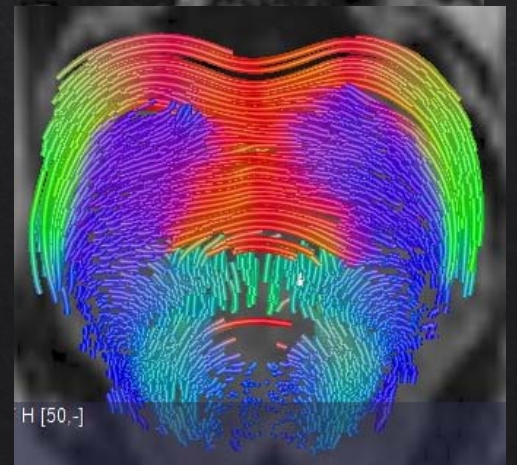
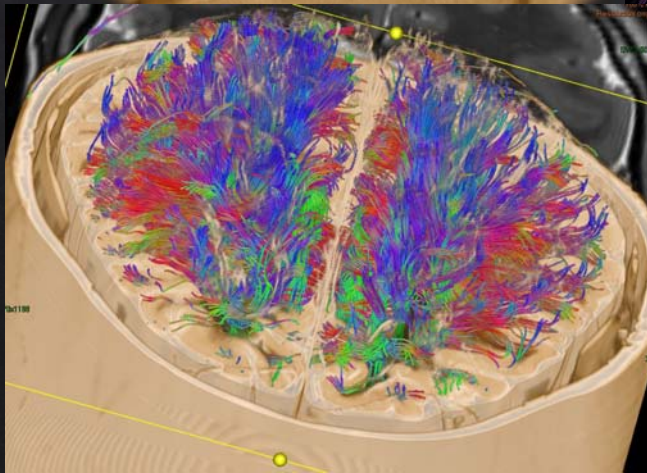
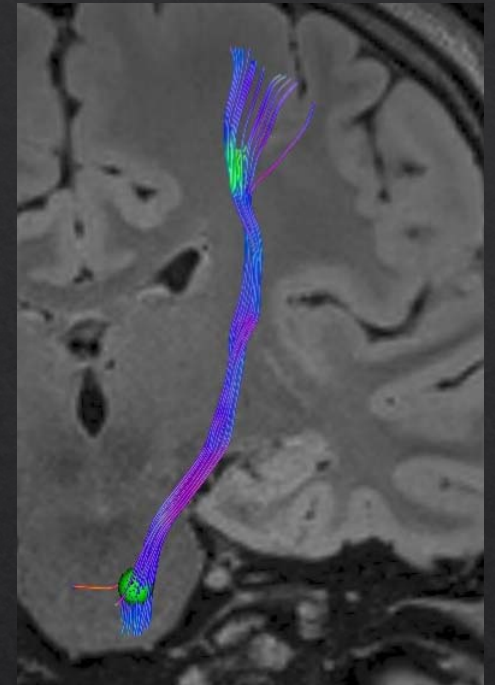
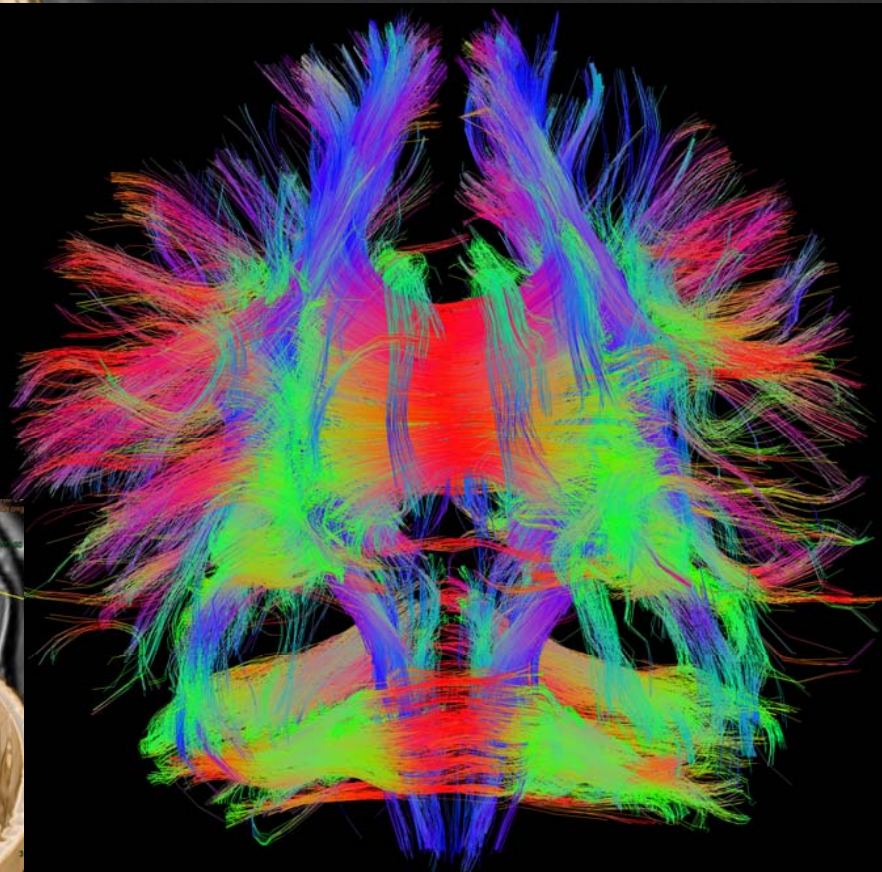
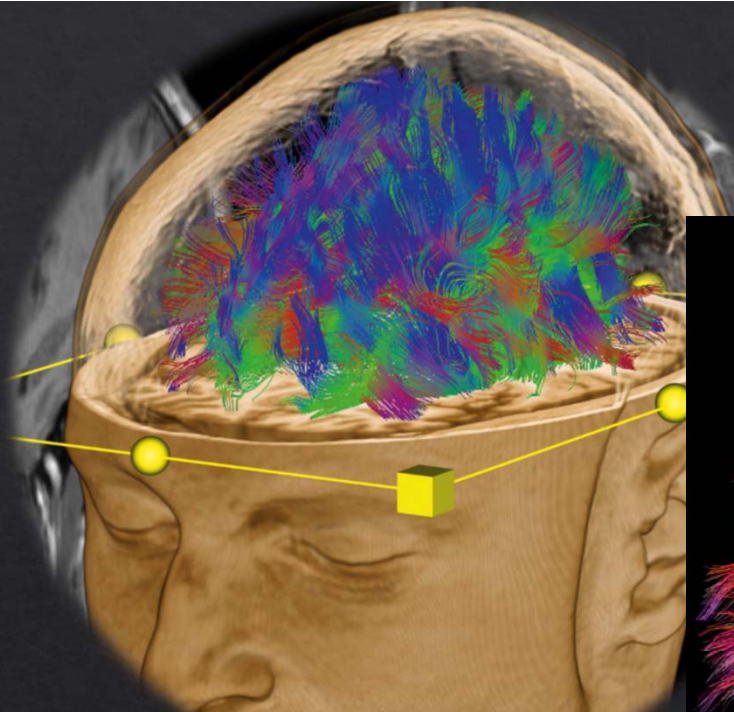
DESPIERTO

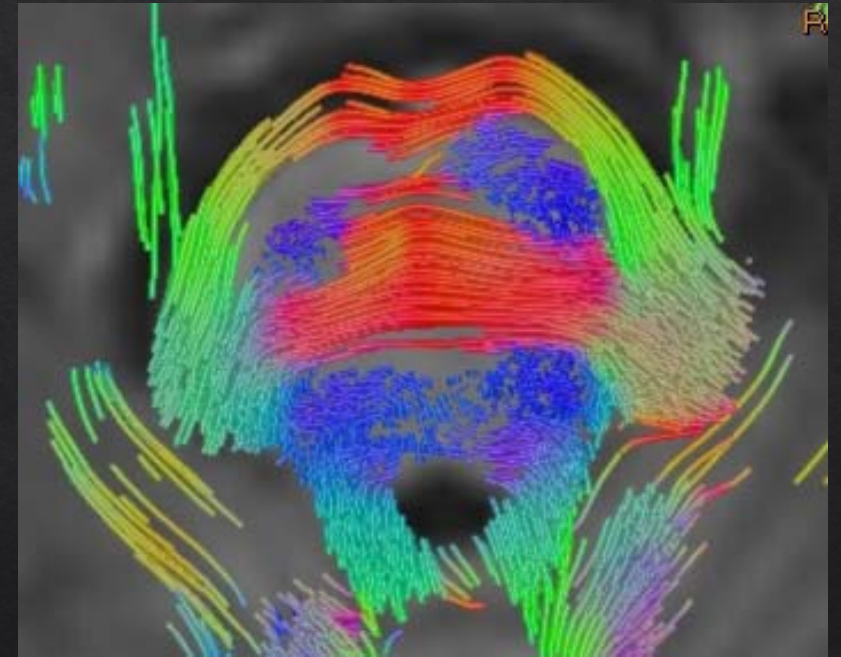
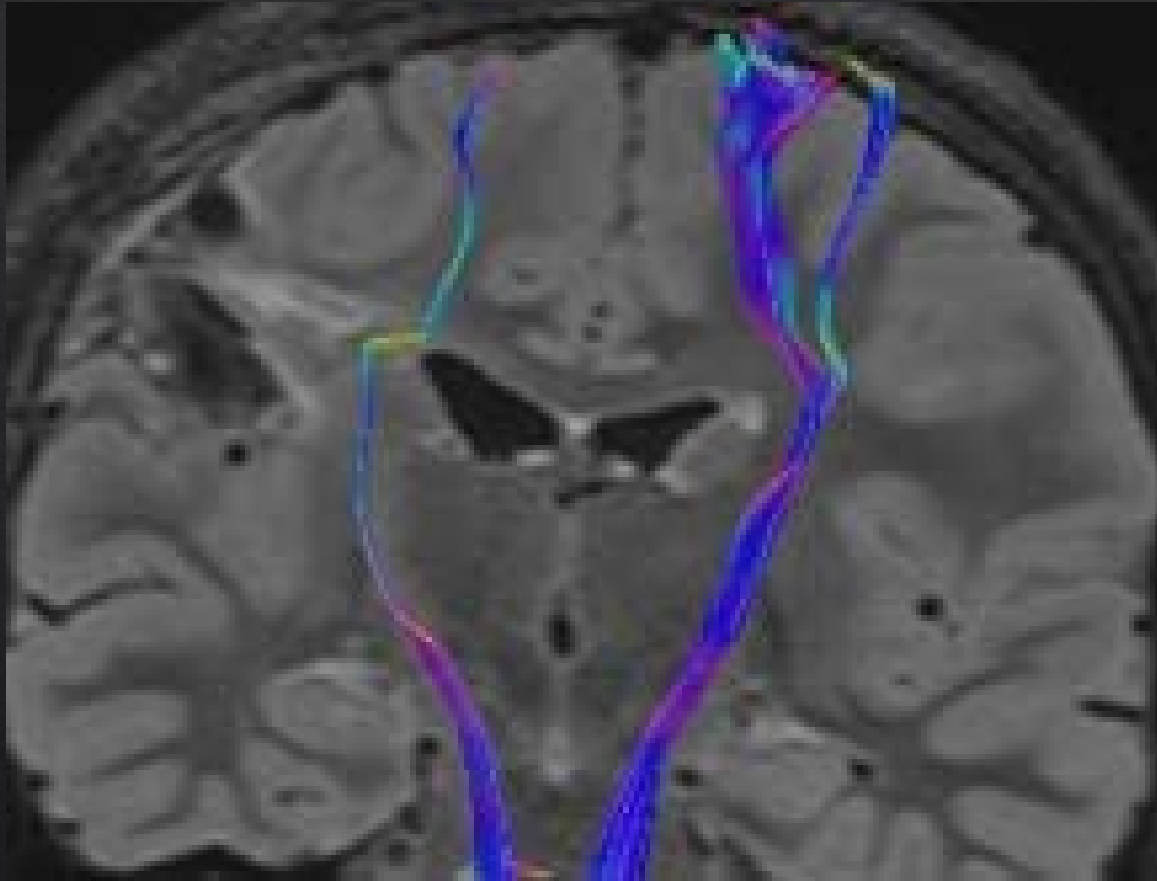
ANESTESIA LEVE

ANESTESIA COMPLETA

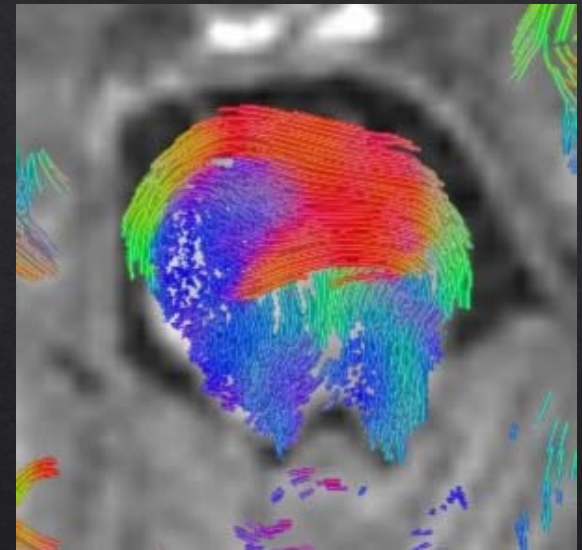
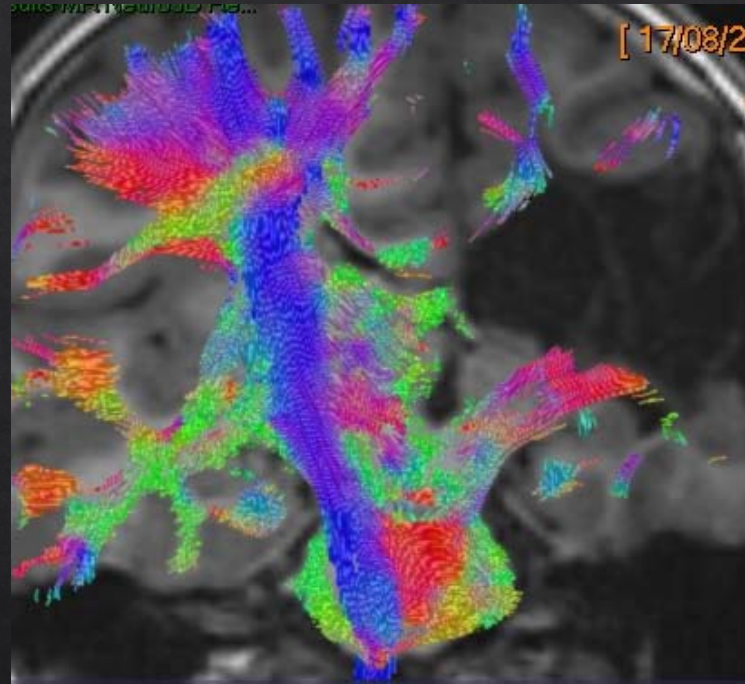
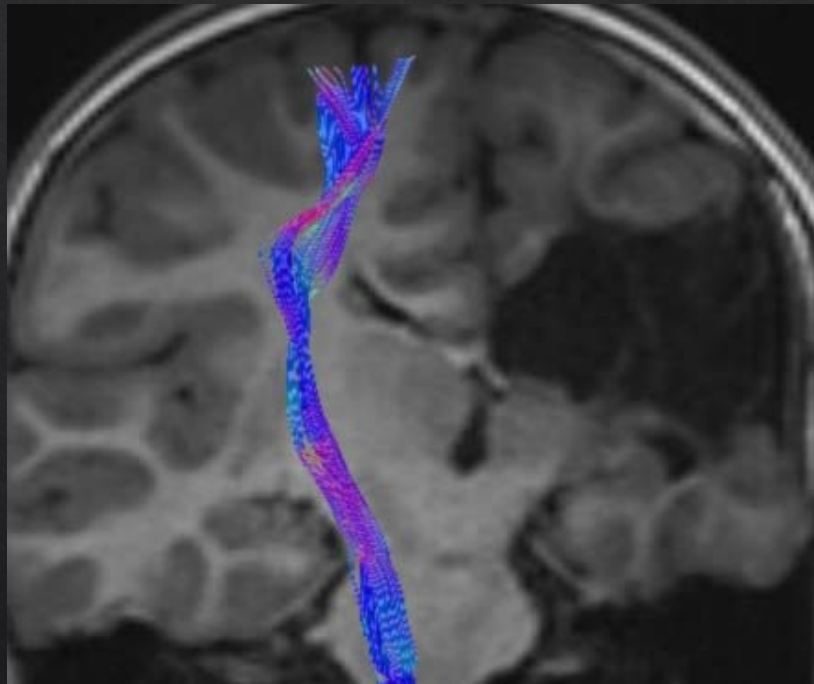




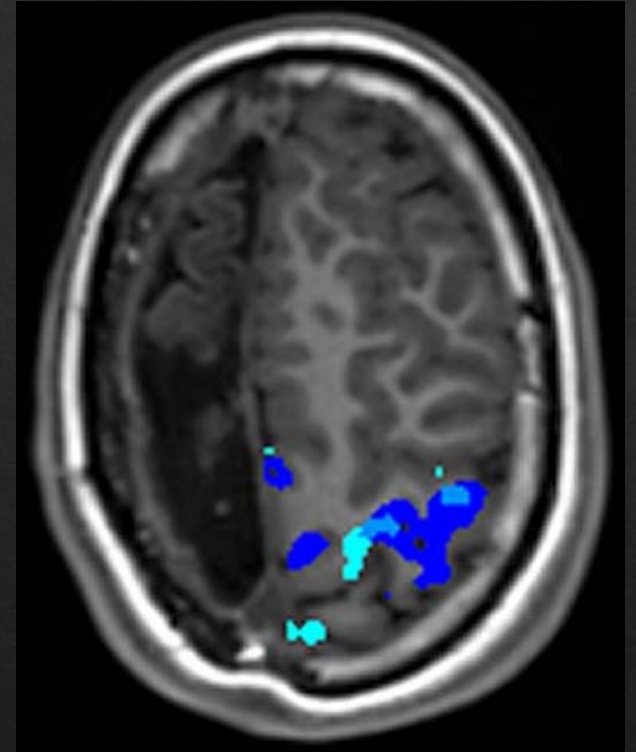
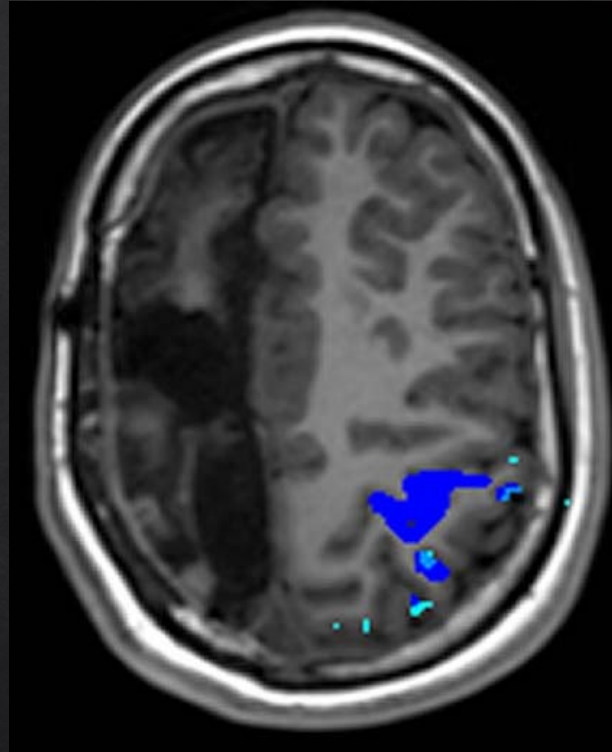
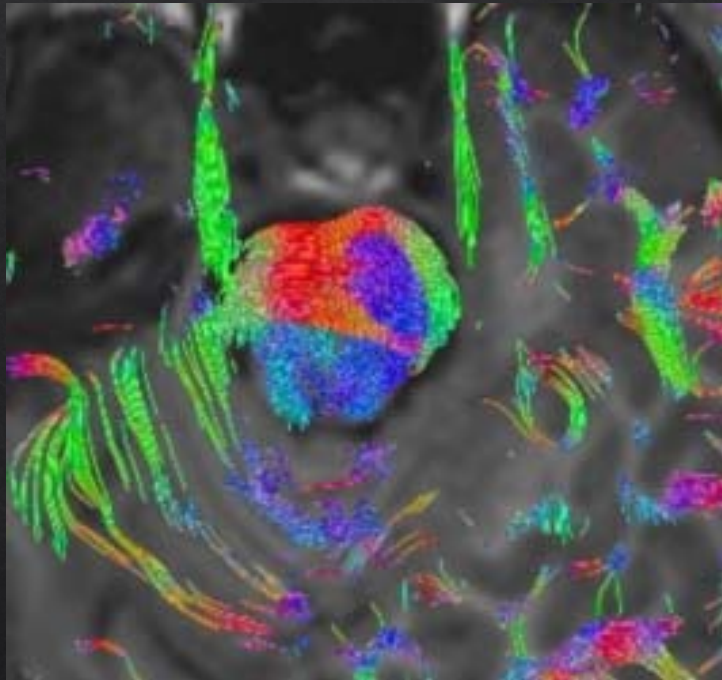




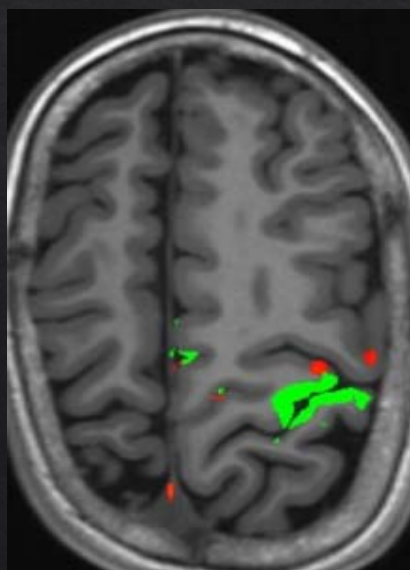
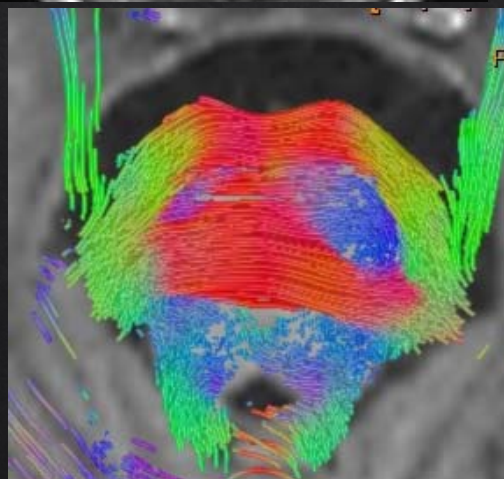
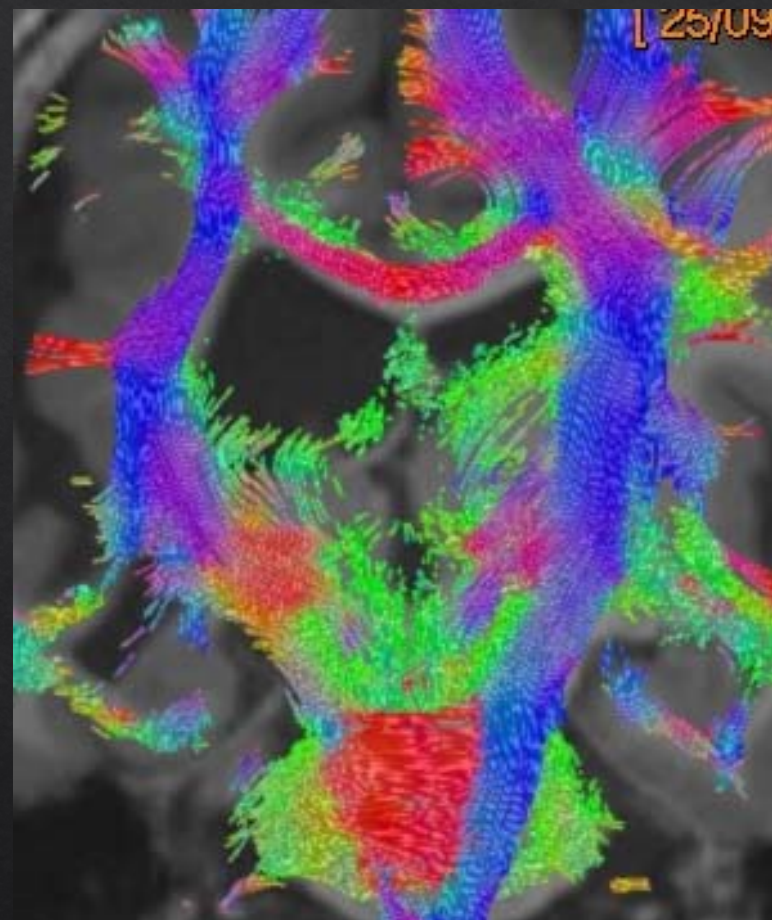
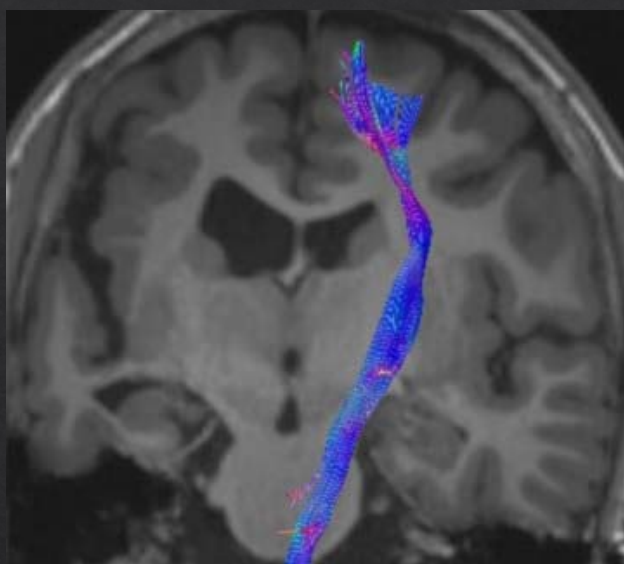
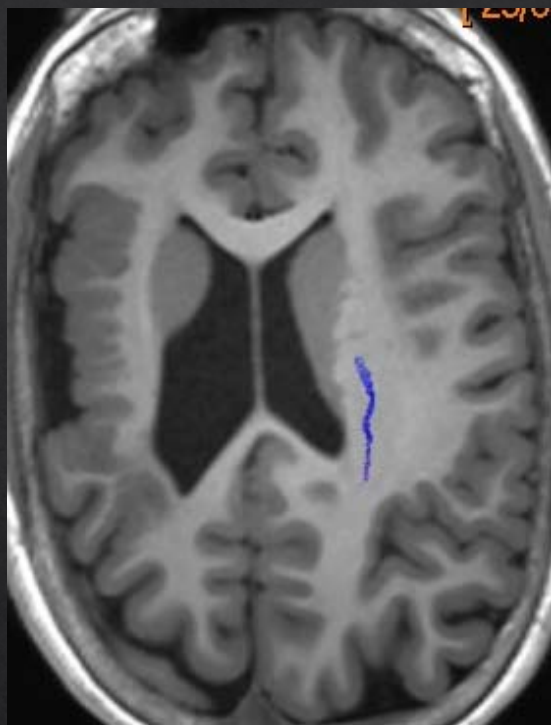
Lesión parcial del TCE: hemiparesia

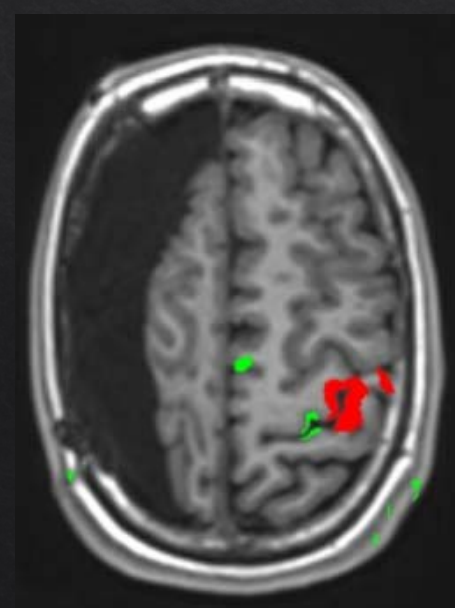
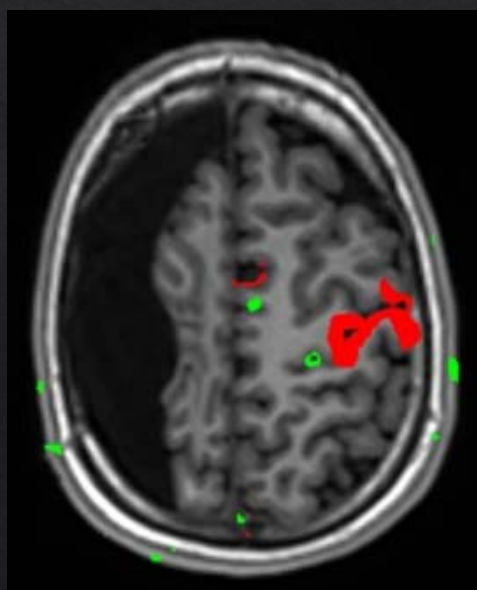
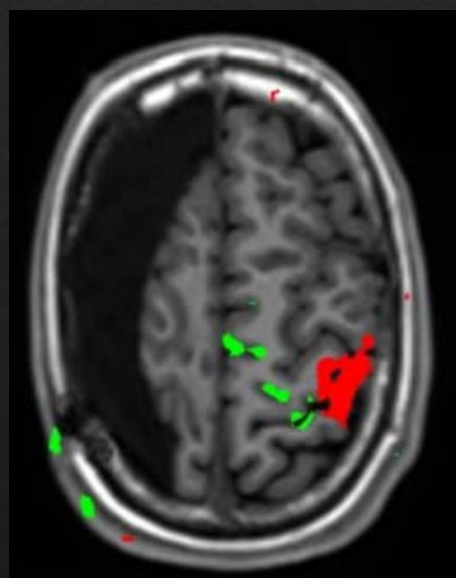
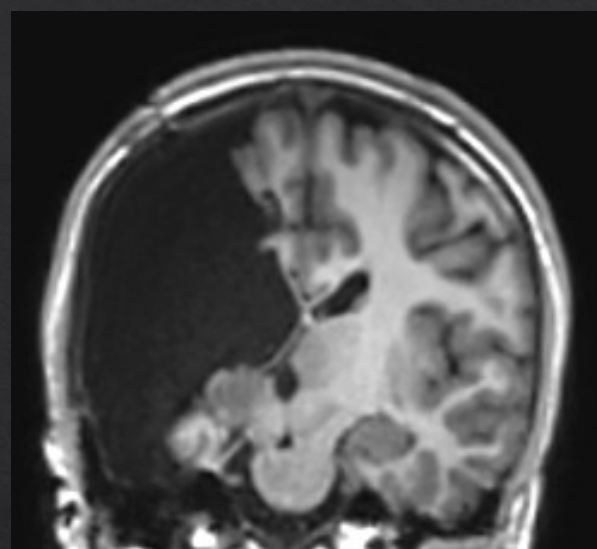
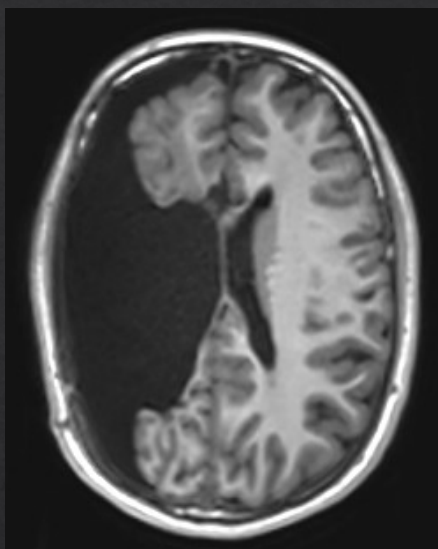


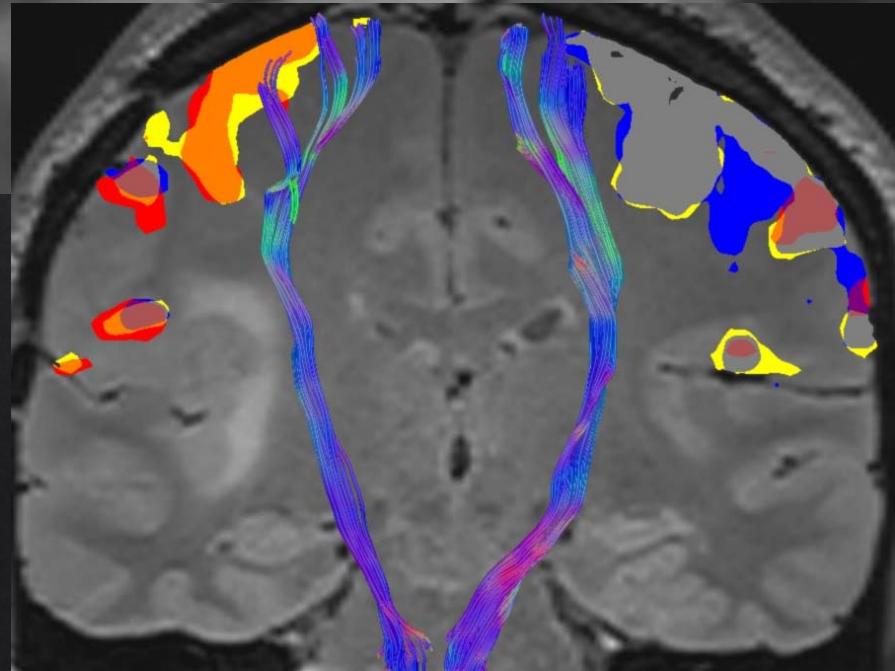
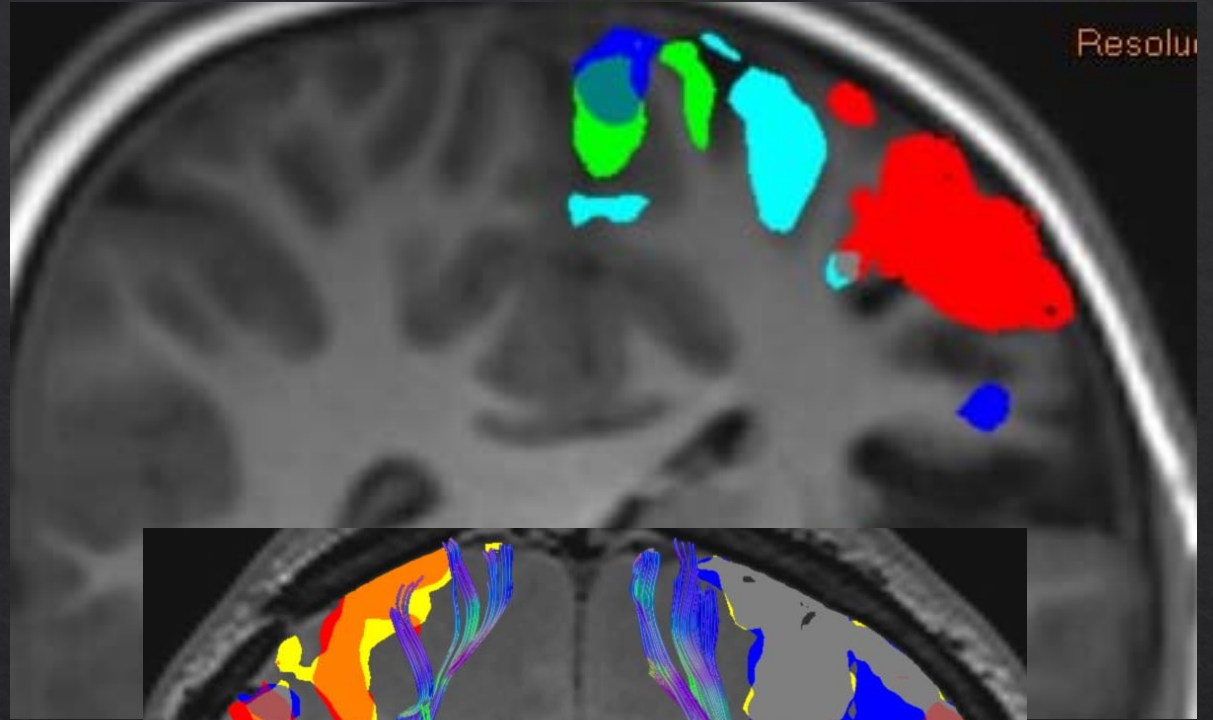
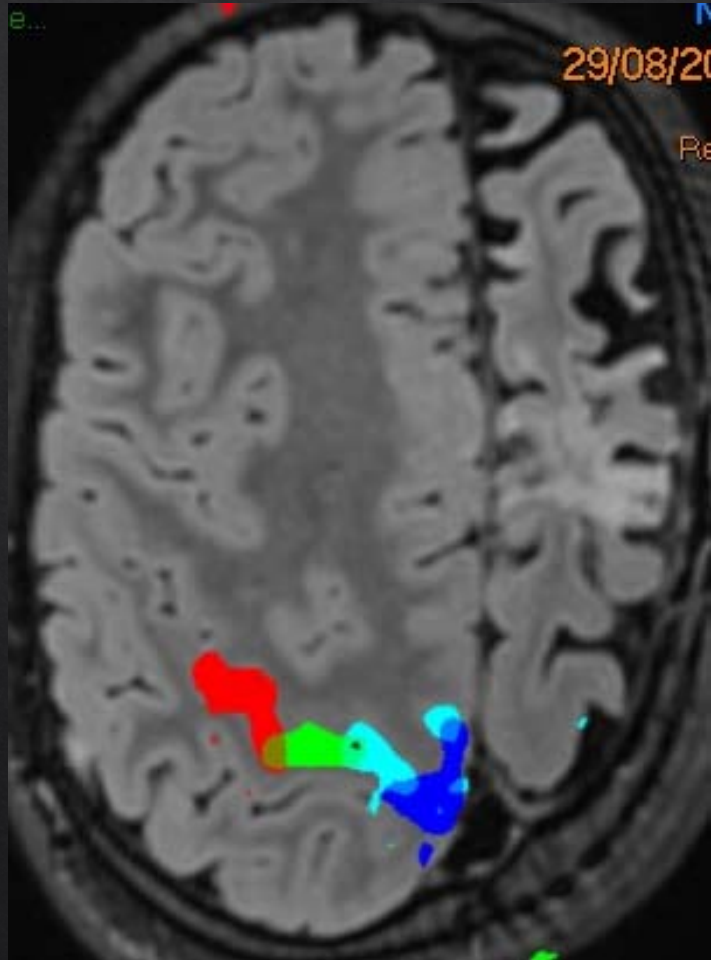
Hemiplejia congénita

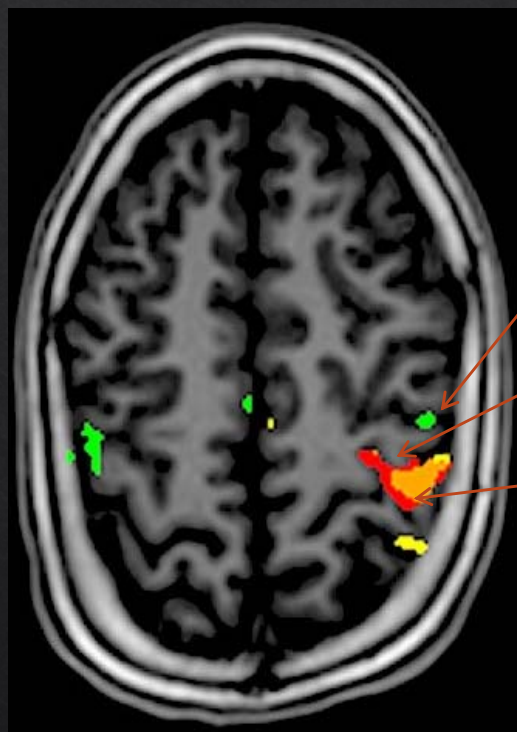


Hemi-PARESIA





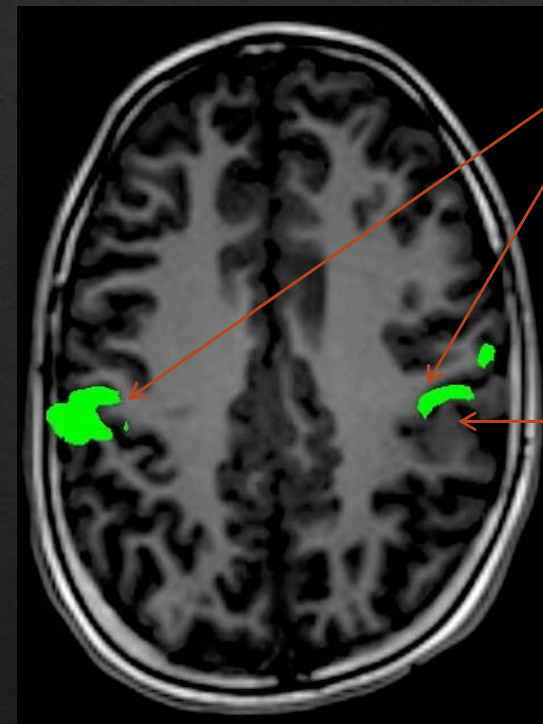
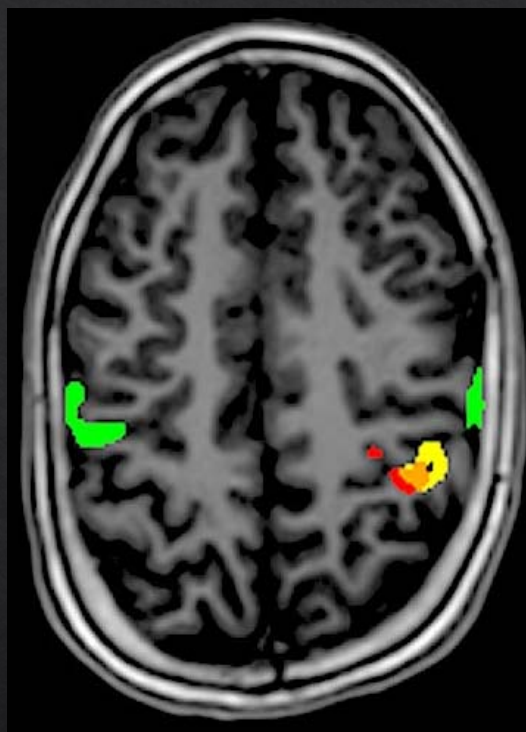




Boca

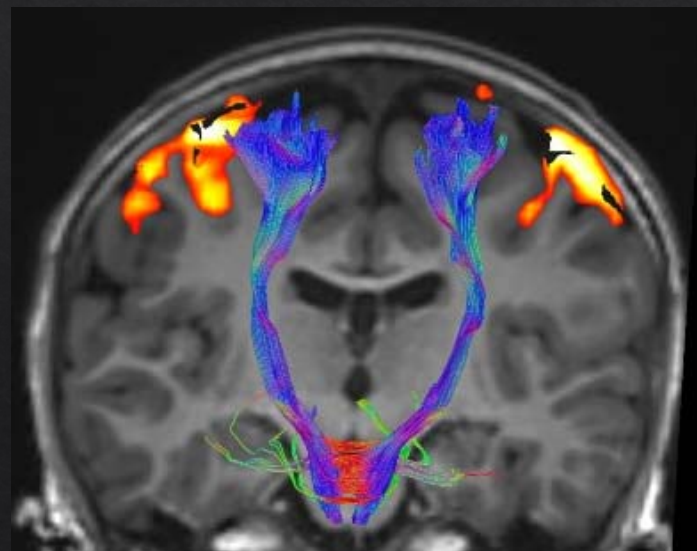
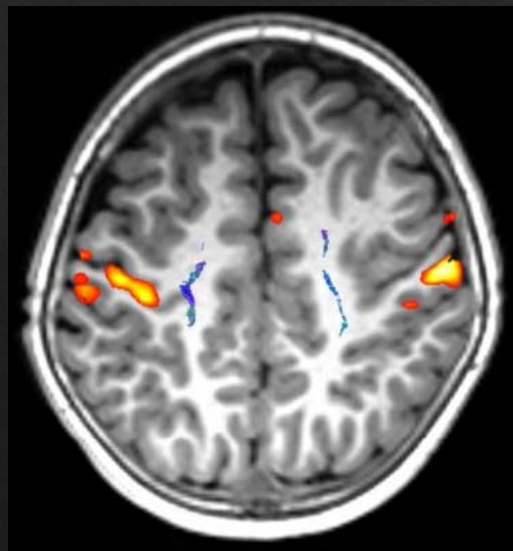
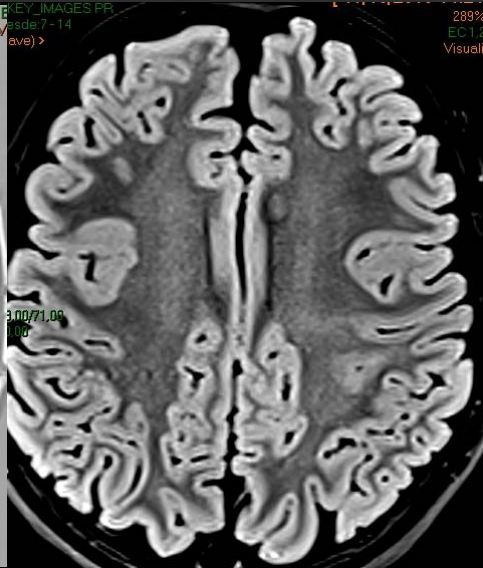
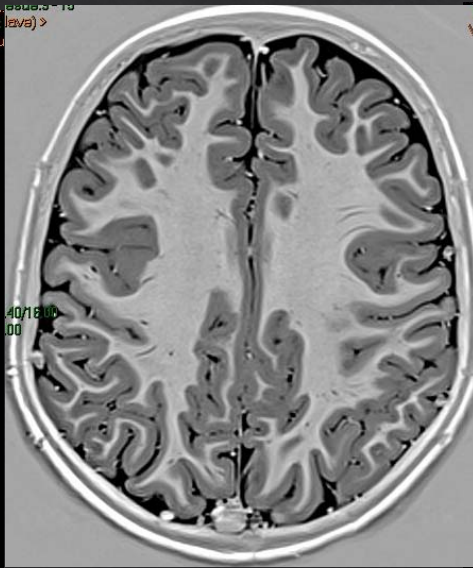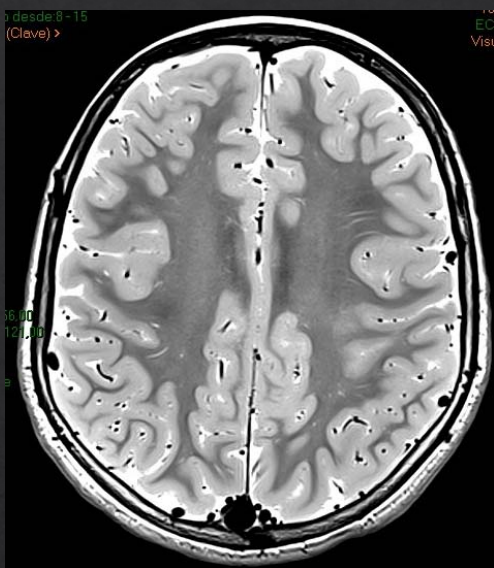
Mano
motor

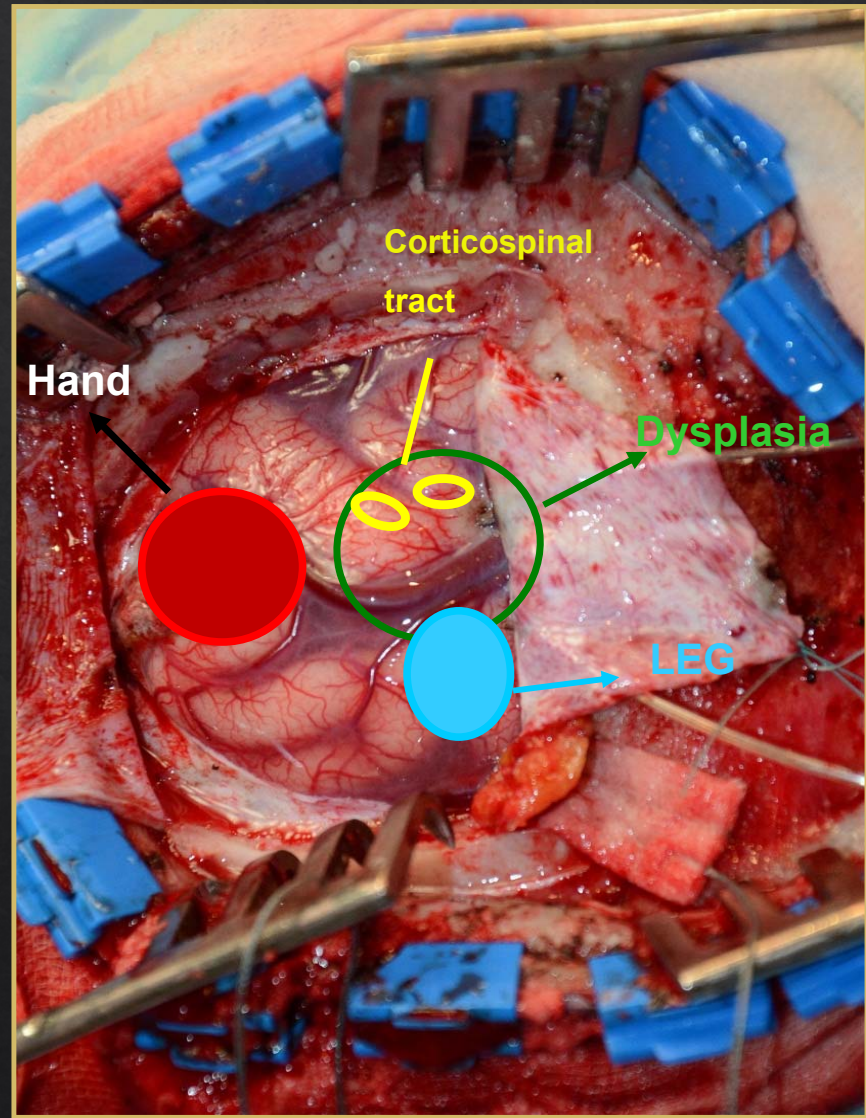
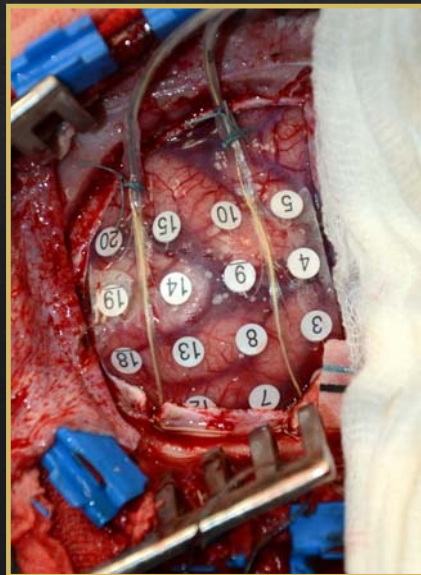
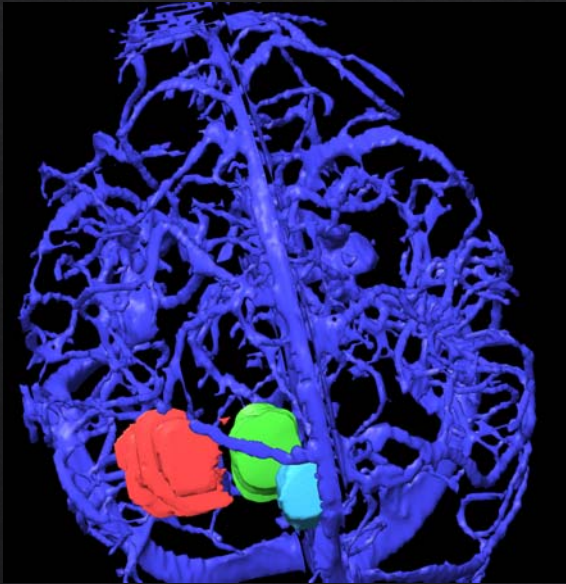
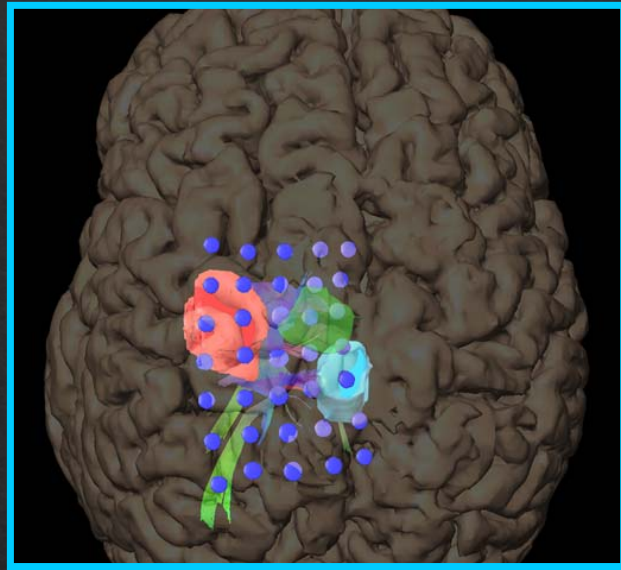
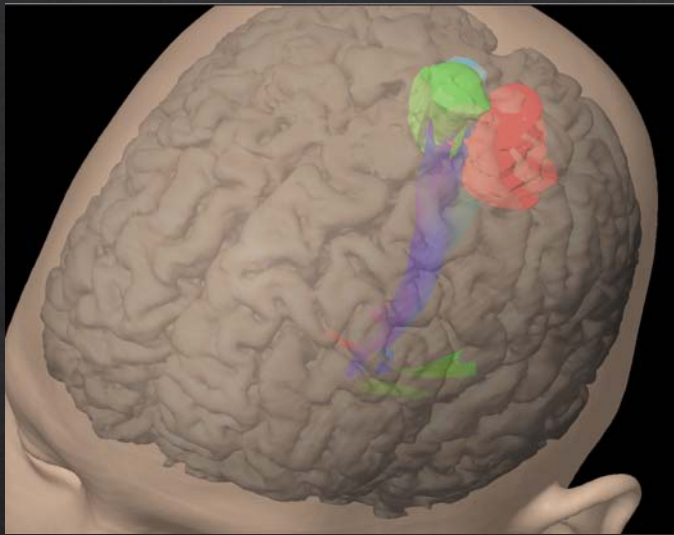
Mano
Sens



Boca

DCF



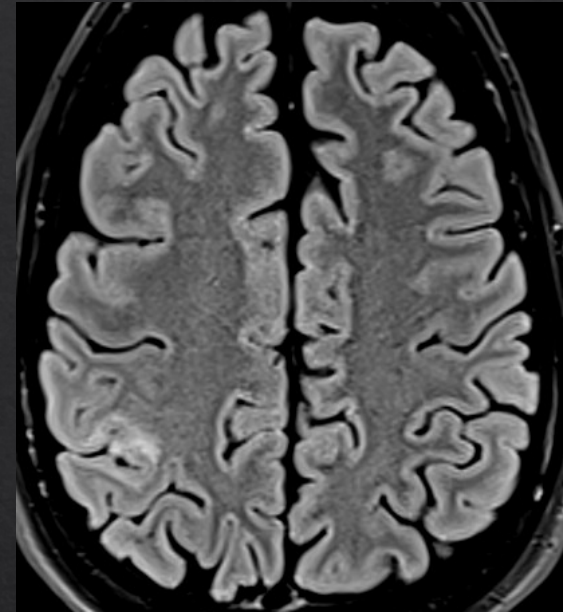
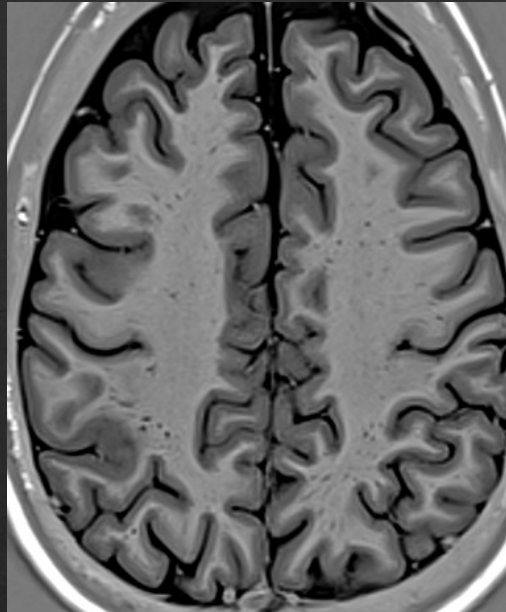


◇ RMf y
Tractografía

◇ Valoración de
riesgo

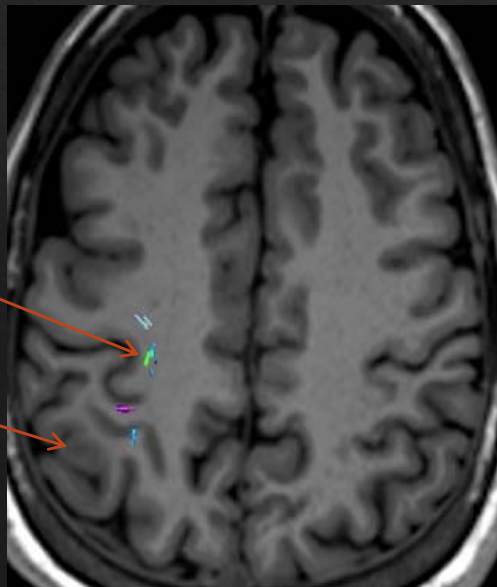
◇ Indicación de ECG

◇ Planificación Q

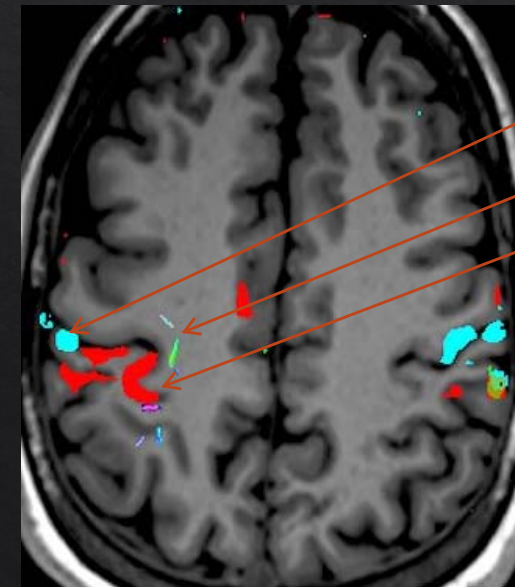


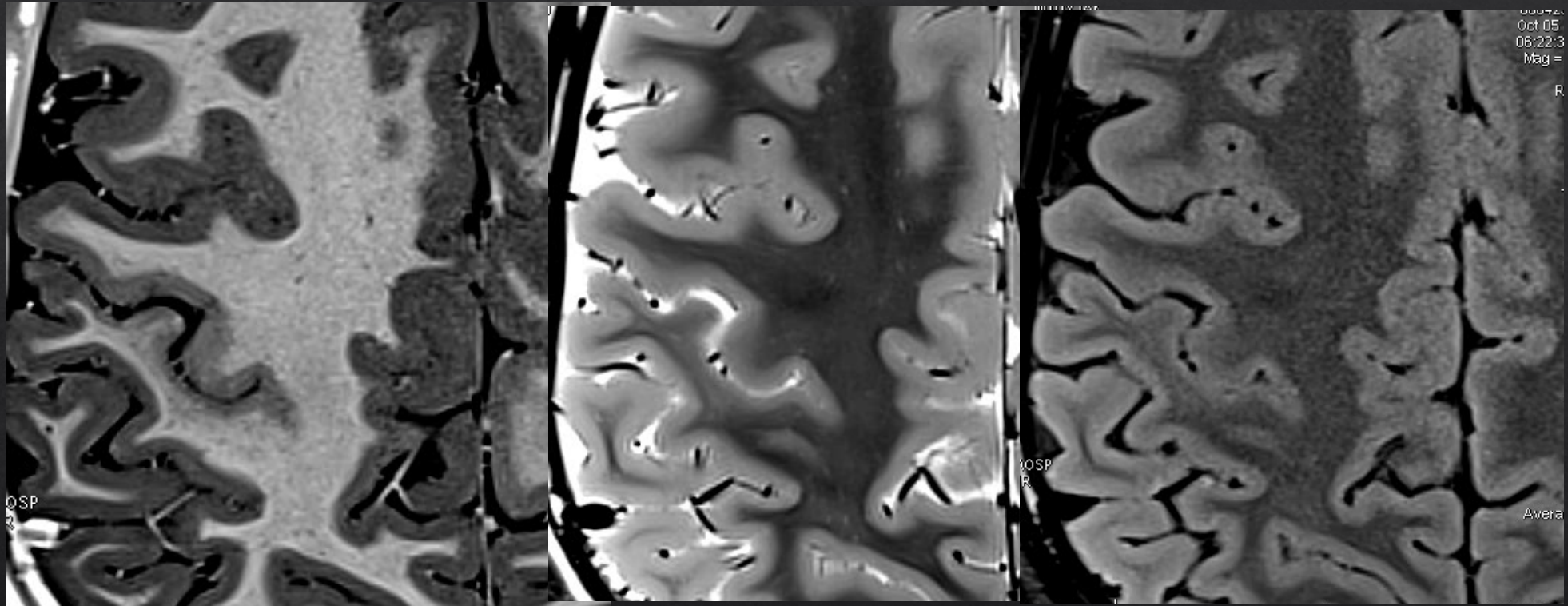
Tracto
Cortico
Espinal
(CST)

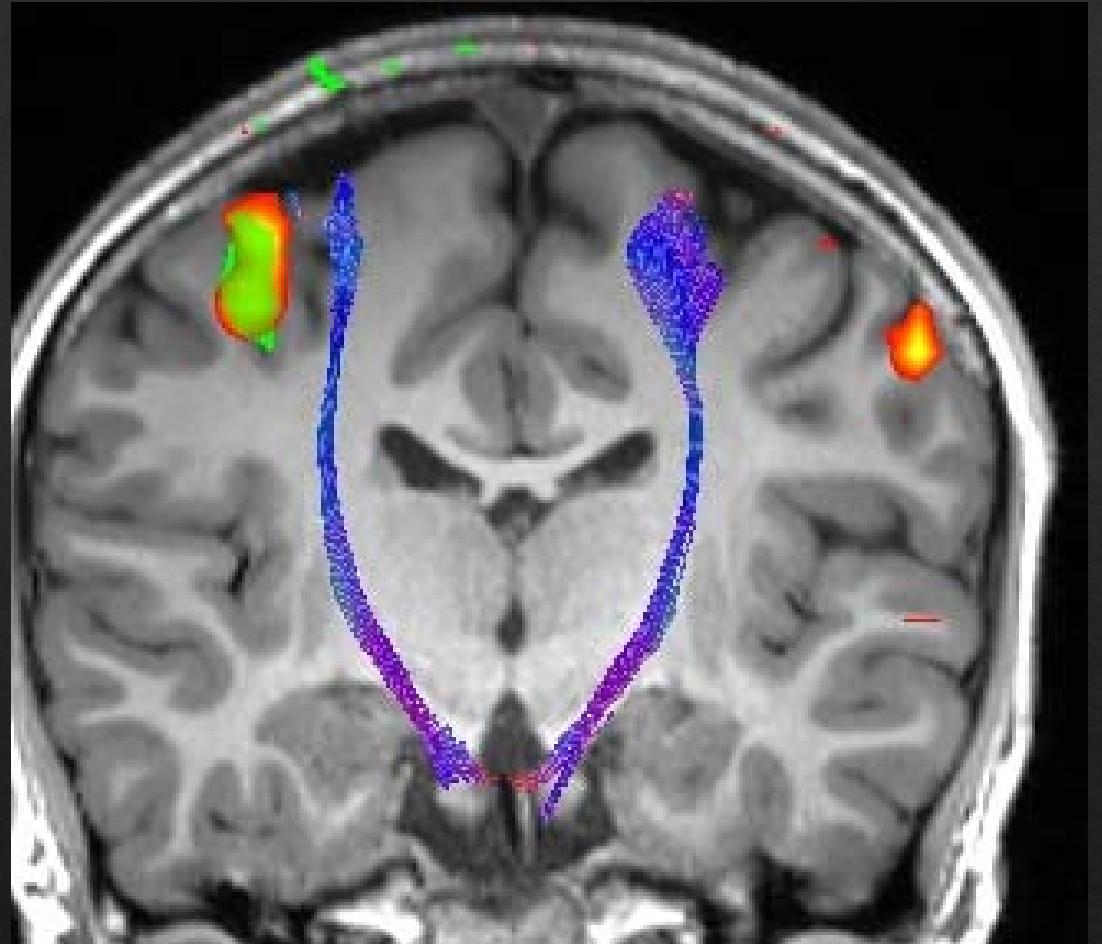
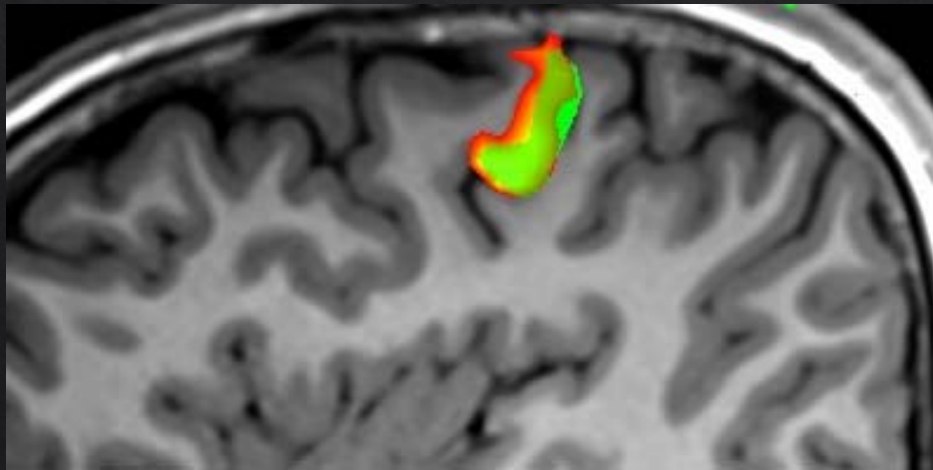
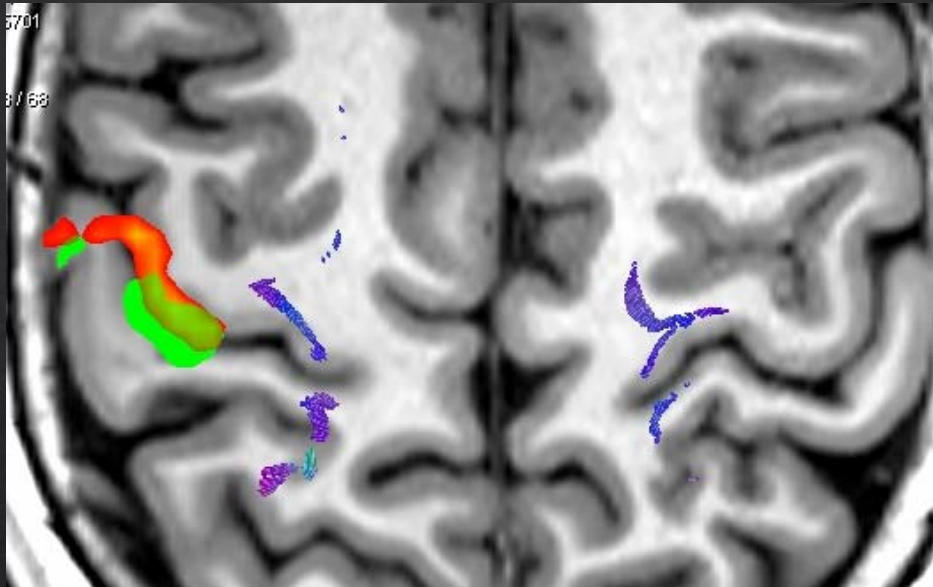
DCF

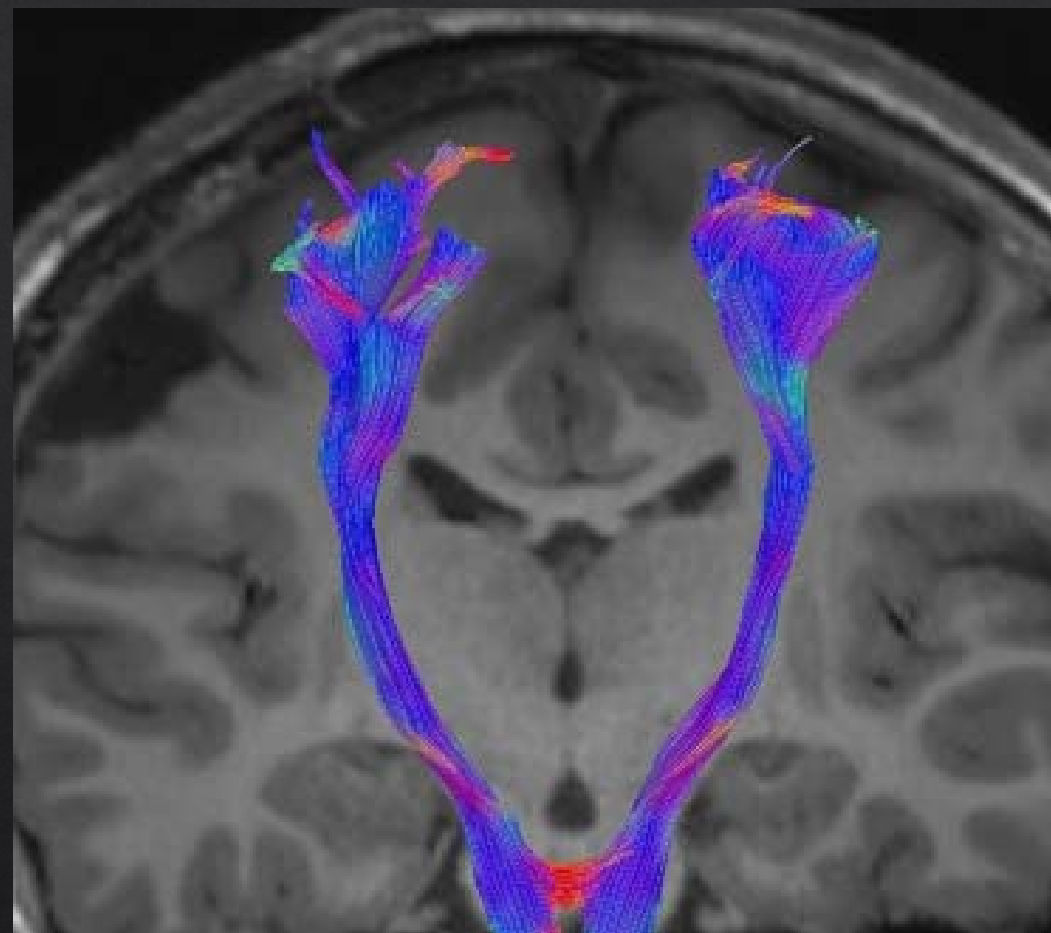
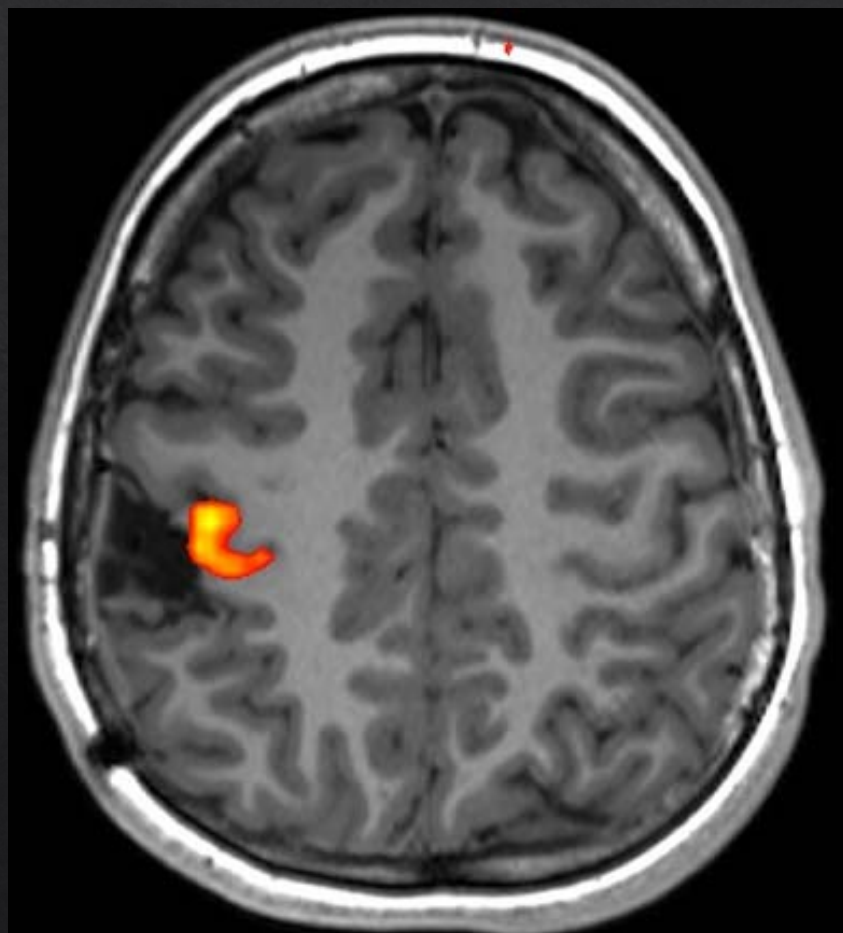


Boca CST
Mano

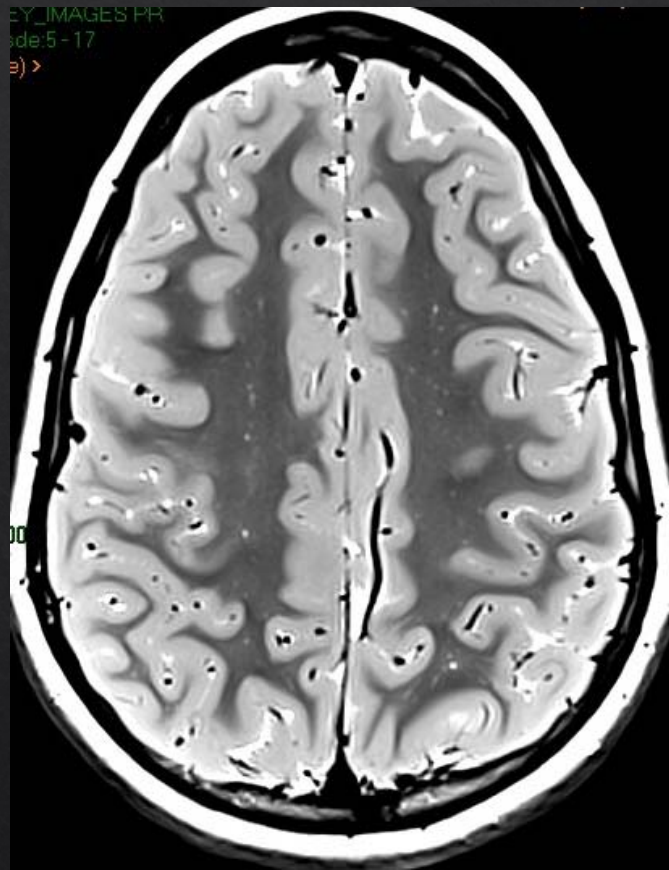




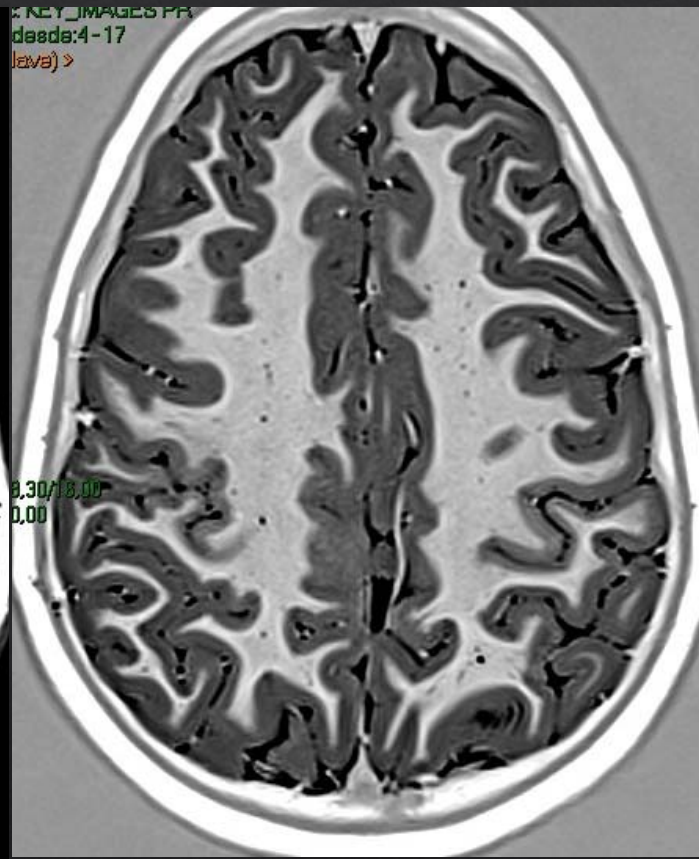




KEY_IMAGES PR
sde:5-17
(e) >

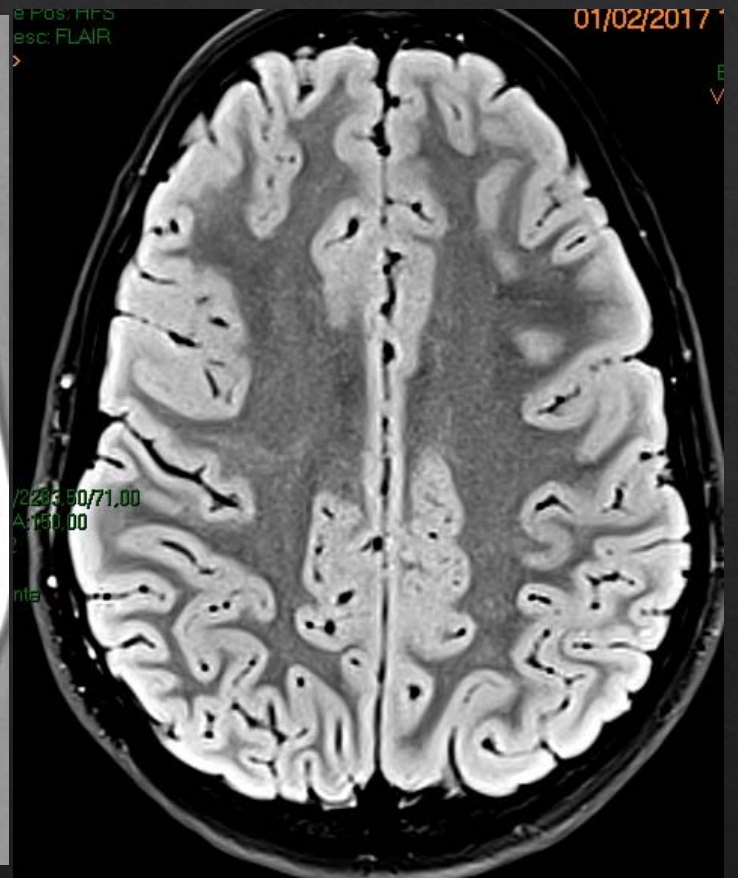


KEY_IMAGES PR
dsds:4-17
(e) >



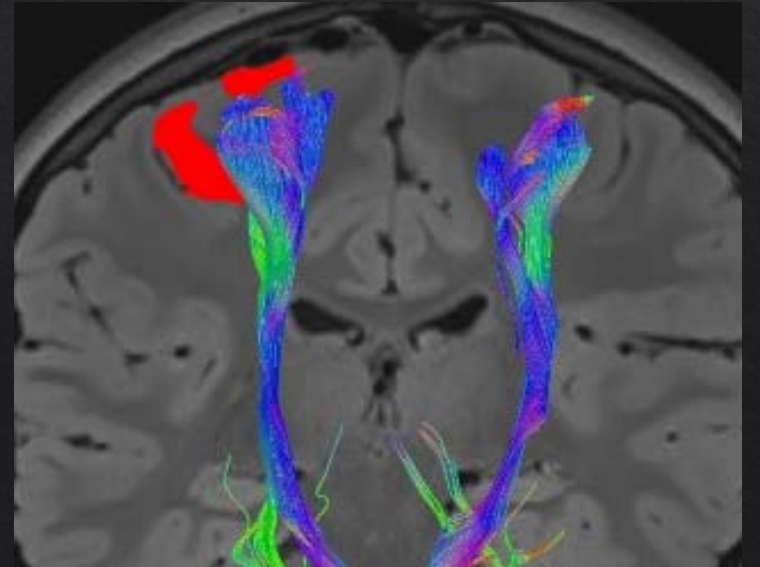
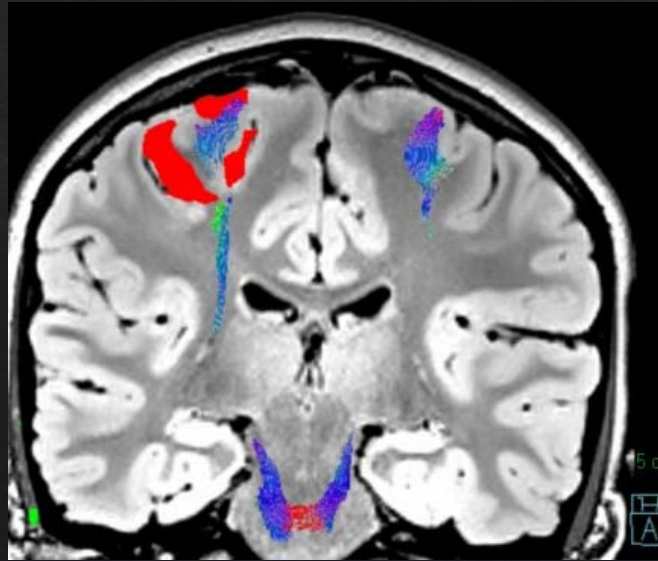
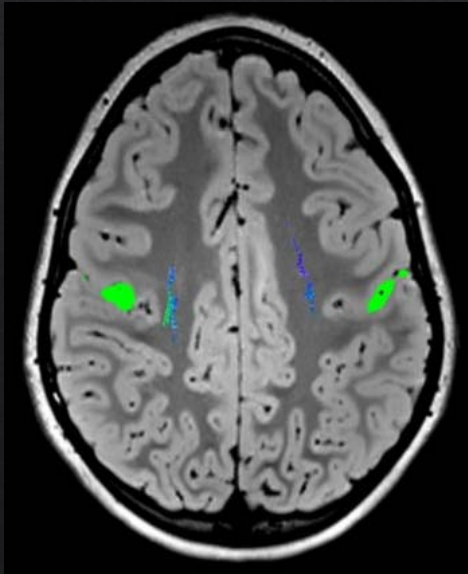
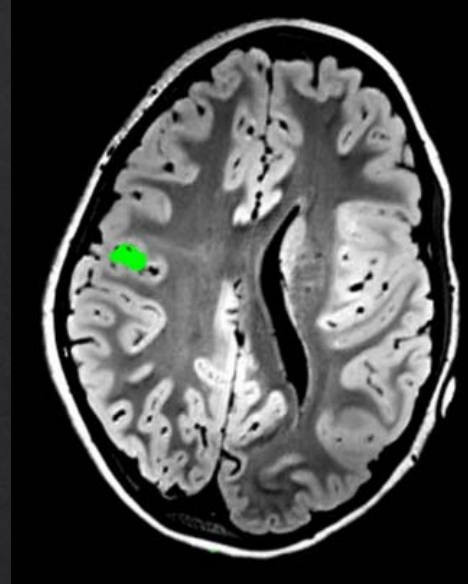
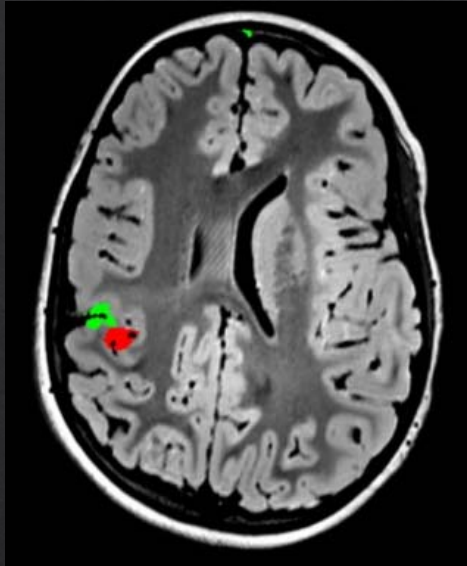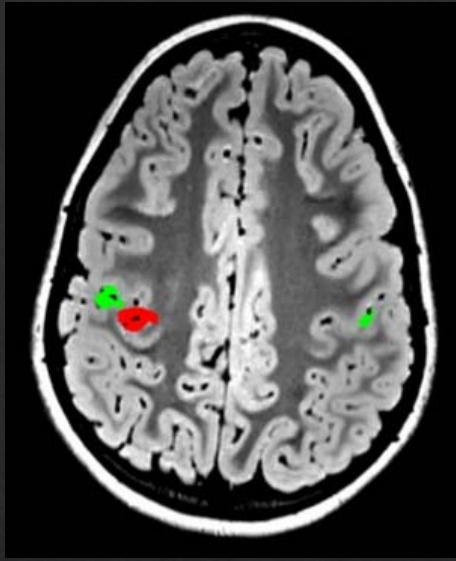
0.30/18.00
0.00

8 Pos: HFS
esc: FLAIR



01/02/2017

223.50/71.00
4.150.00



DMEz
504735

Ty 1 😊
VERTICAL

Ty2
VERTICAL

Ty3 😊
VERTICAL
Mon intro ⭐

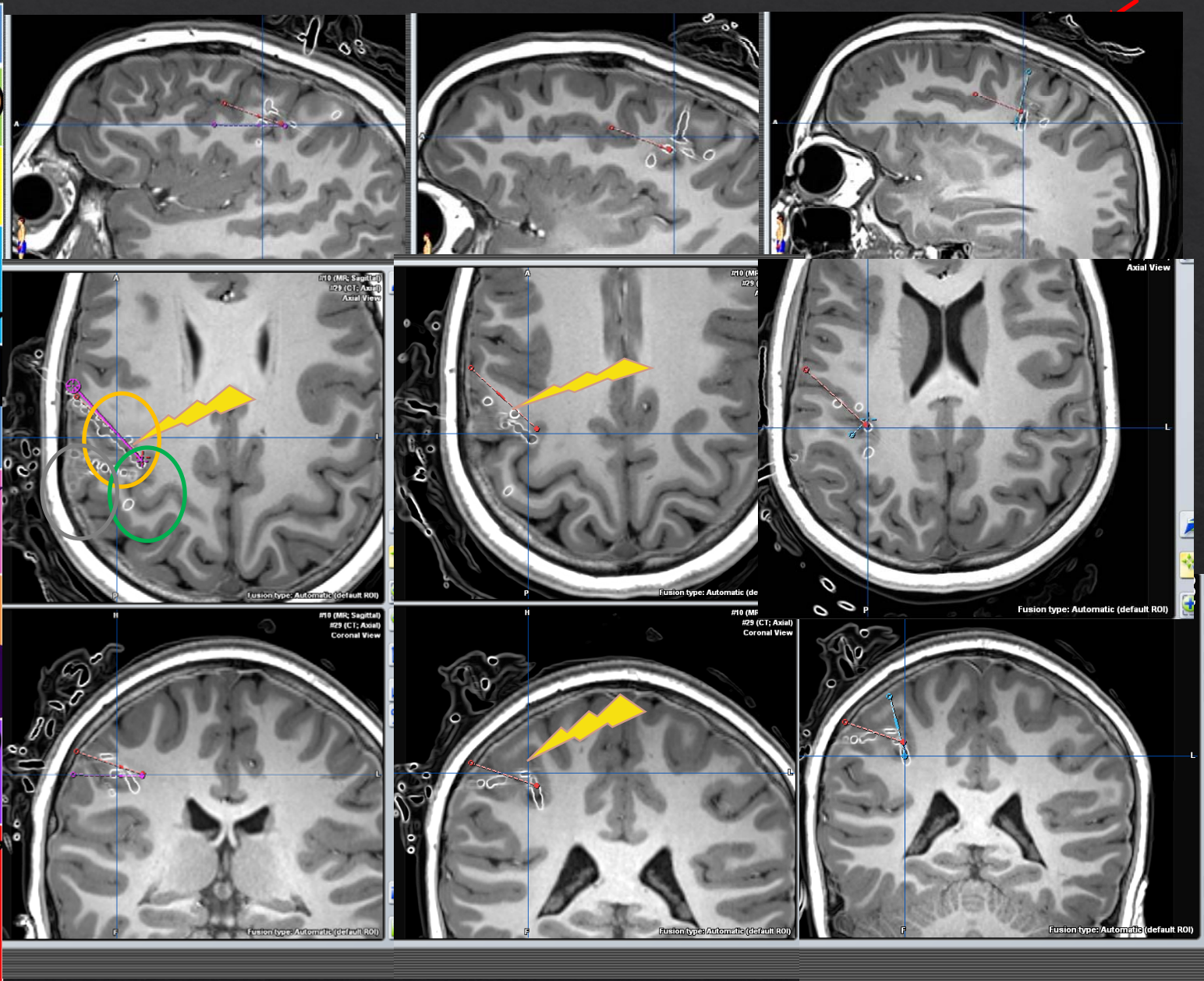Ty4 * 🖐️
VERTICAL
Mon intro

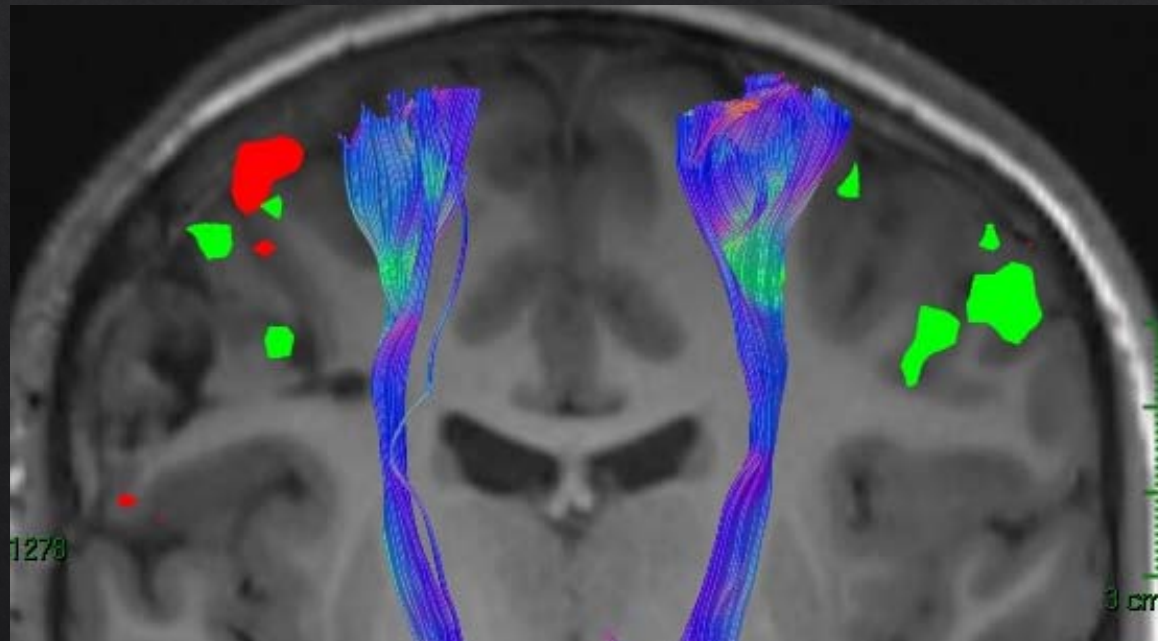
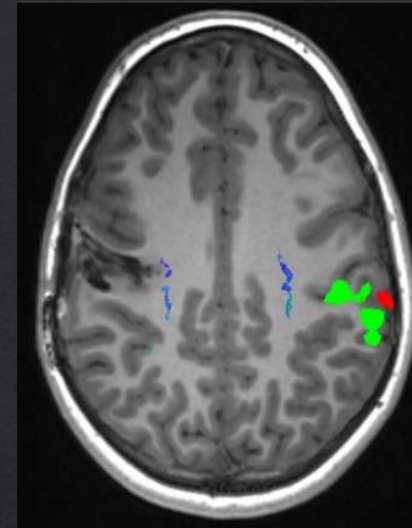
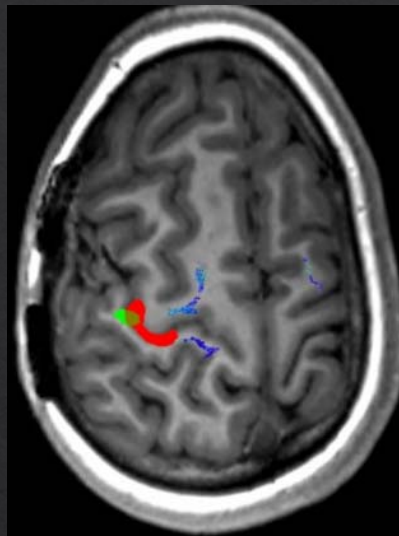
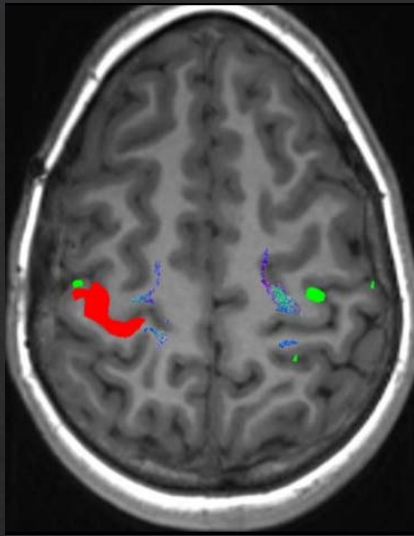
Ty5 ⭐
ORTOGONAL

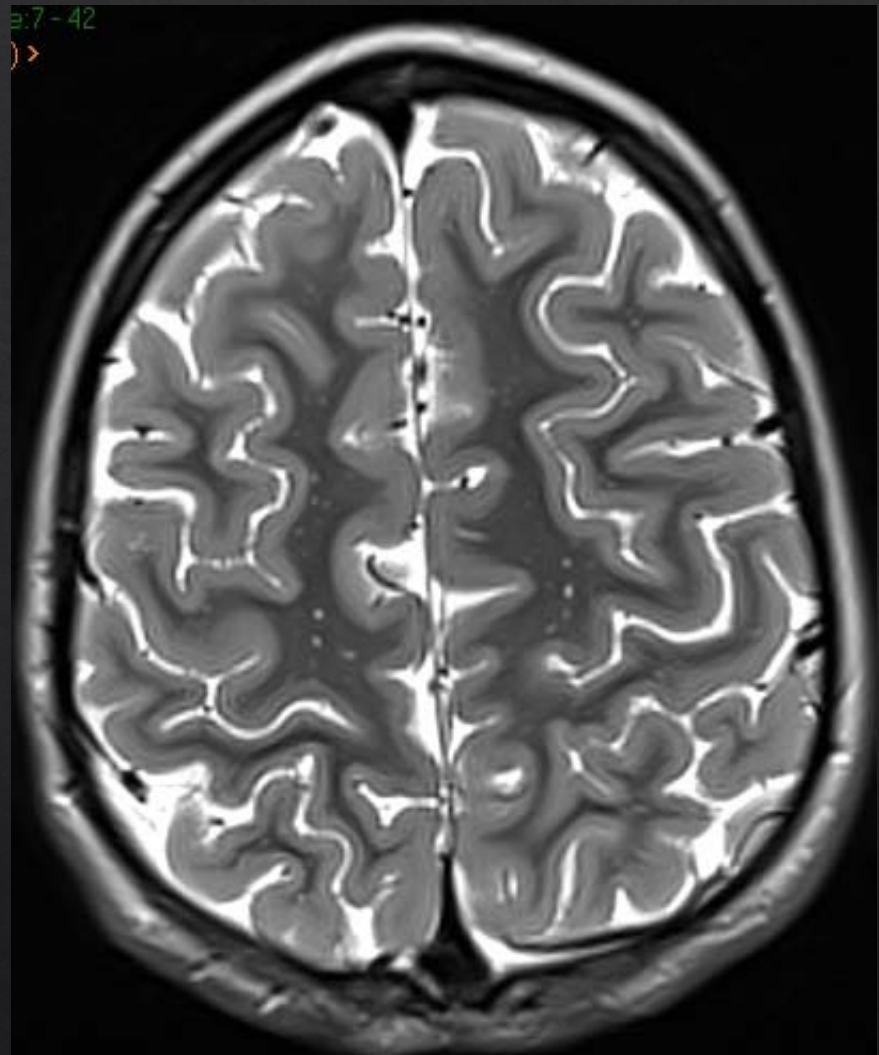
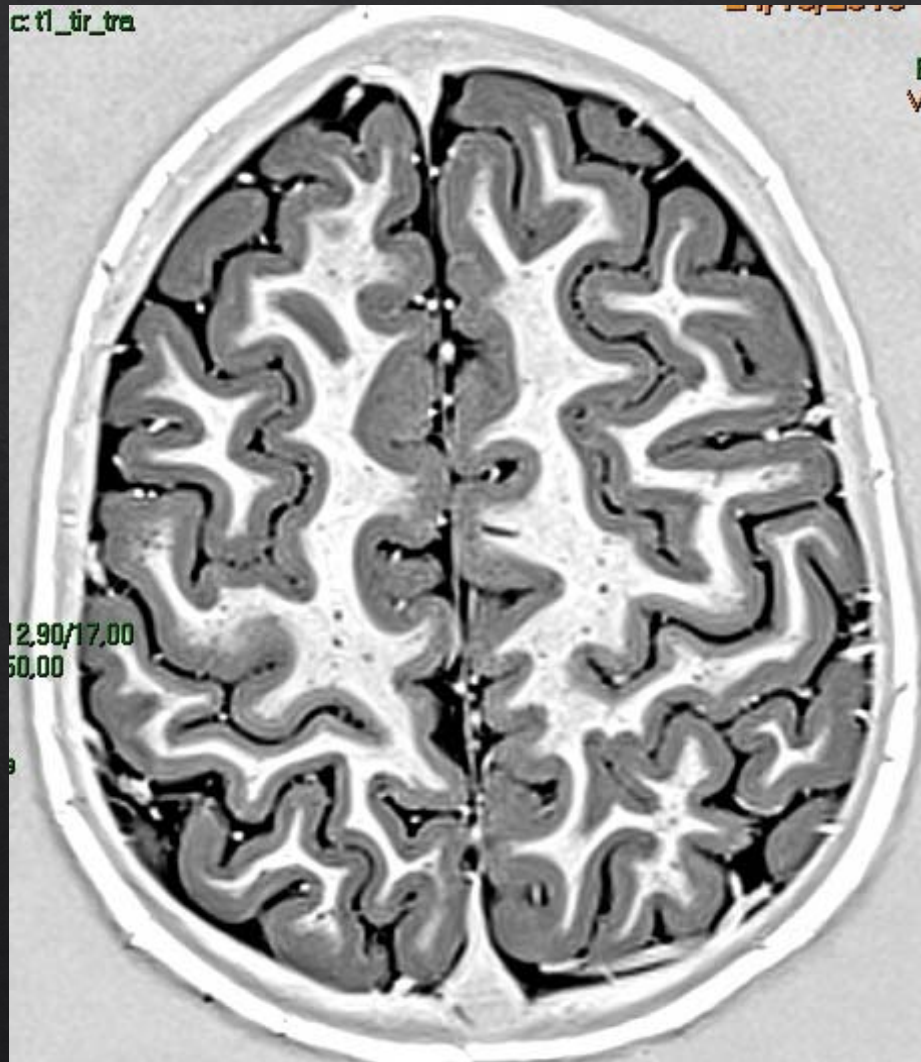Ty6
ORTOGONAL
🖐️

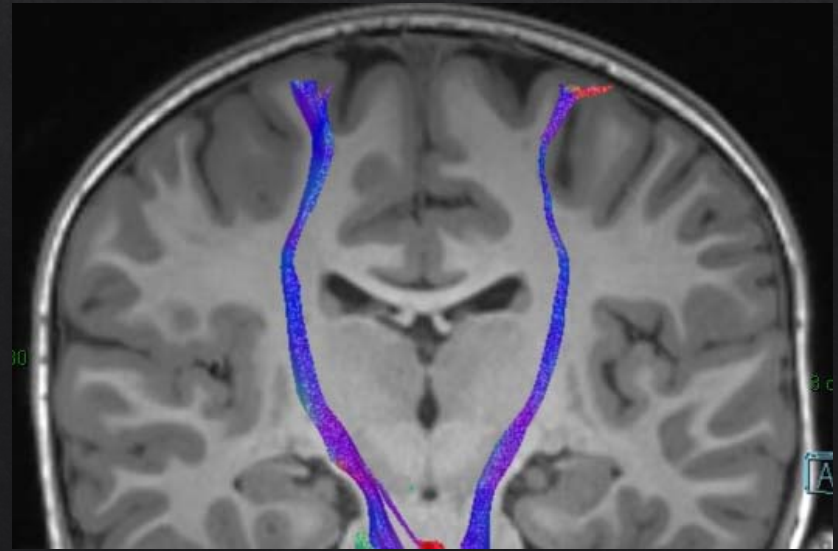
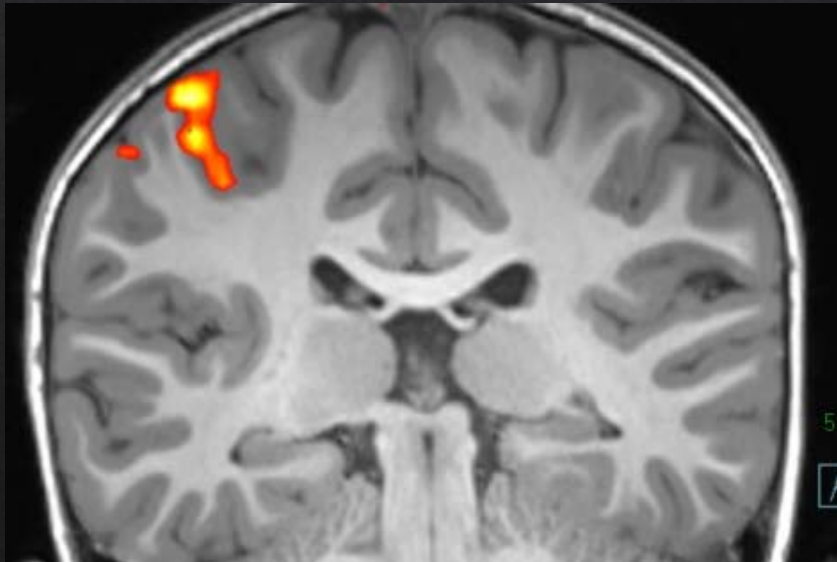
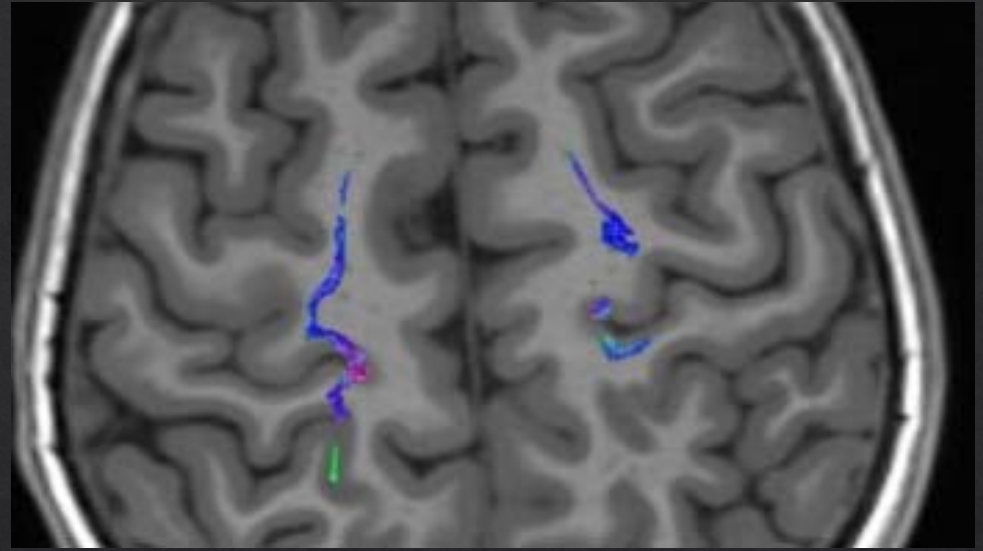
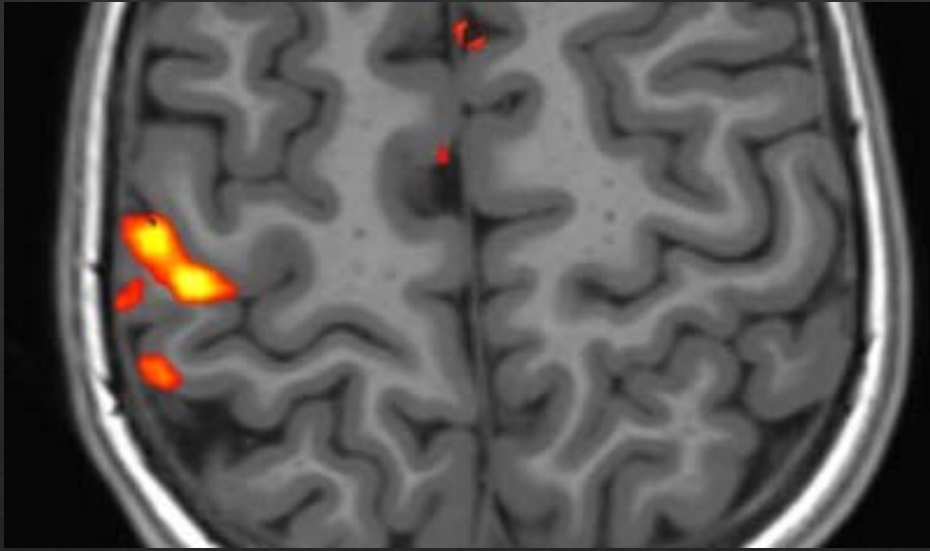
Ty7 😊
ORTOGONAL

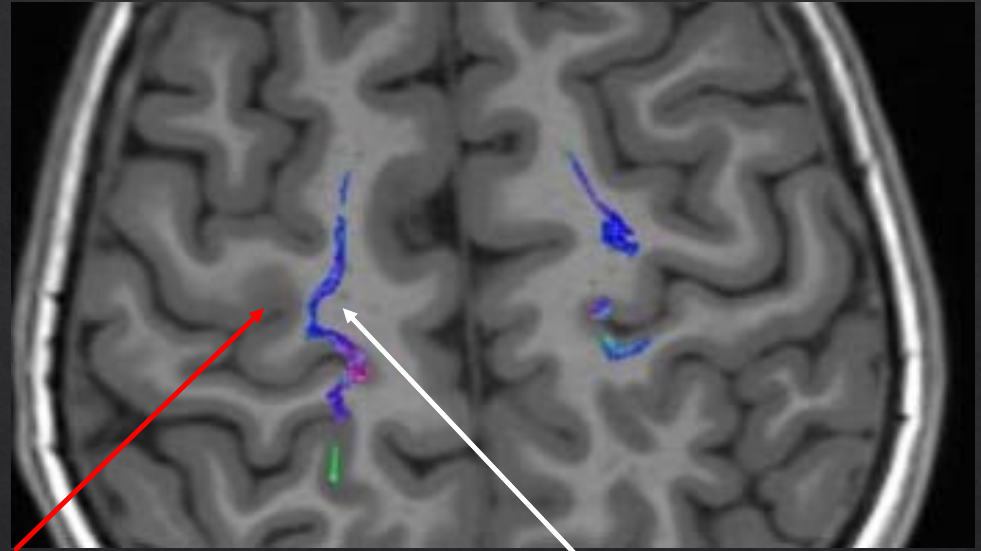
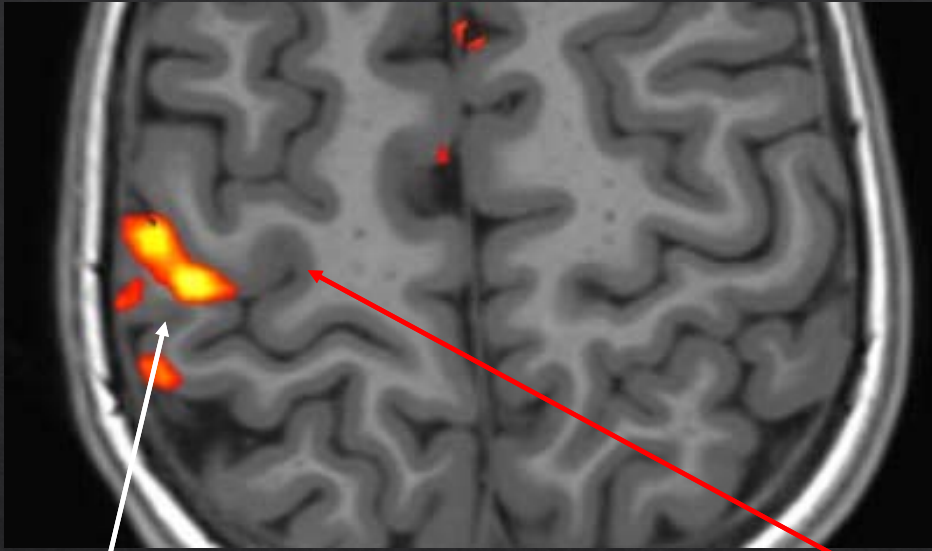
Ty8 ⭐
ORTOGONAL



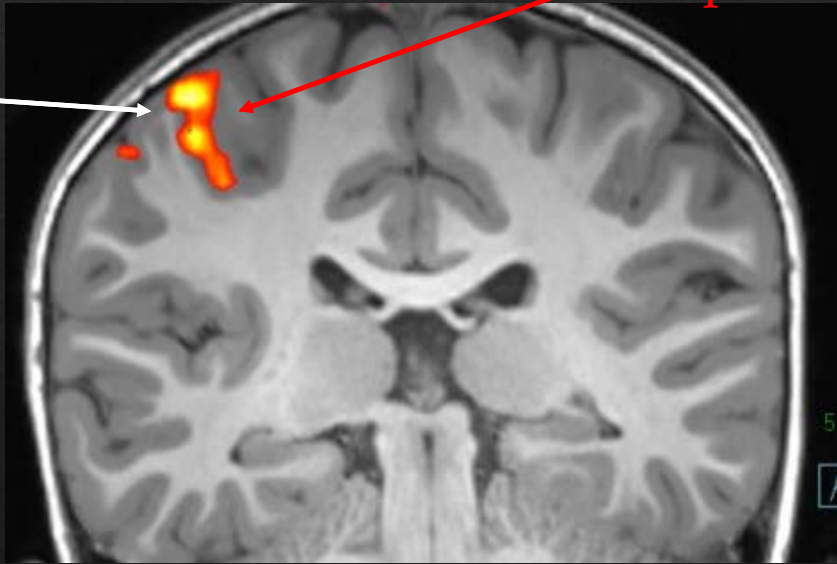




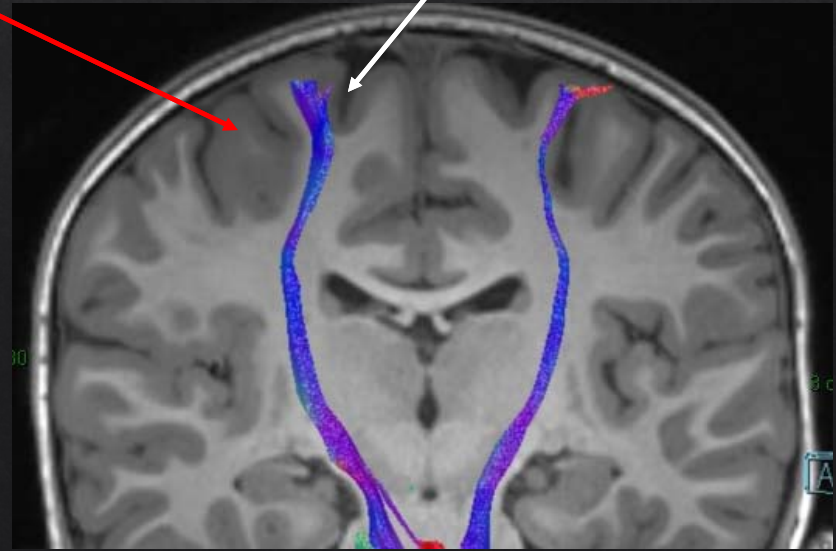




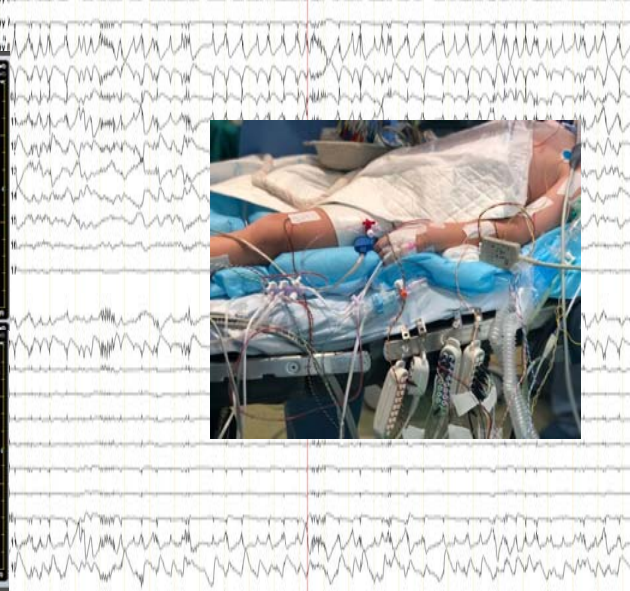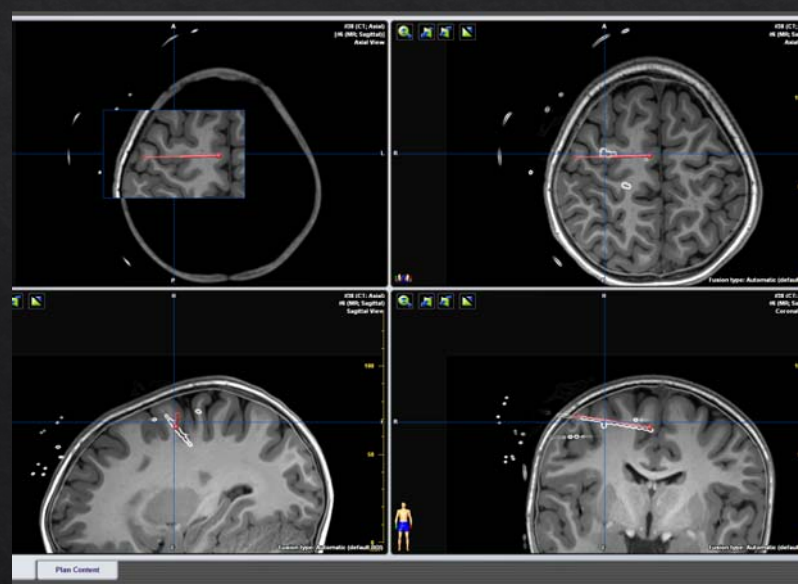
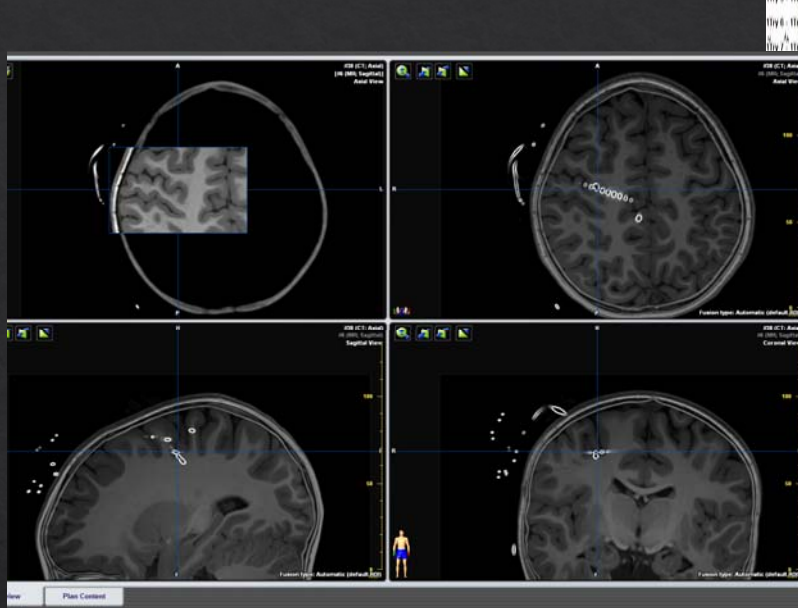
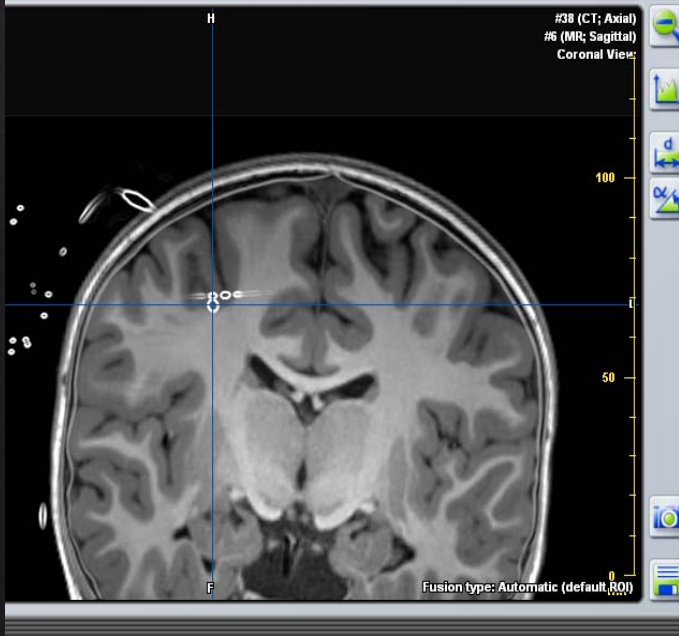
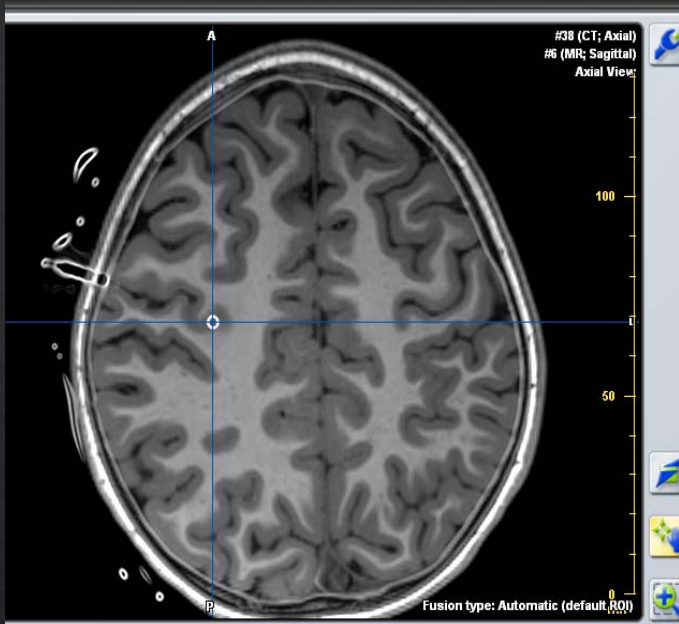
Mano

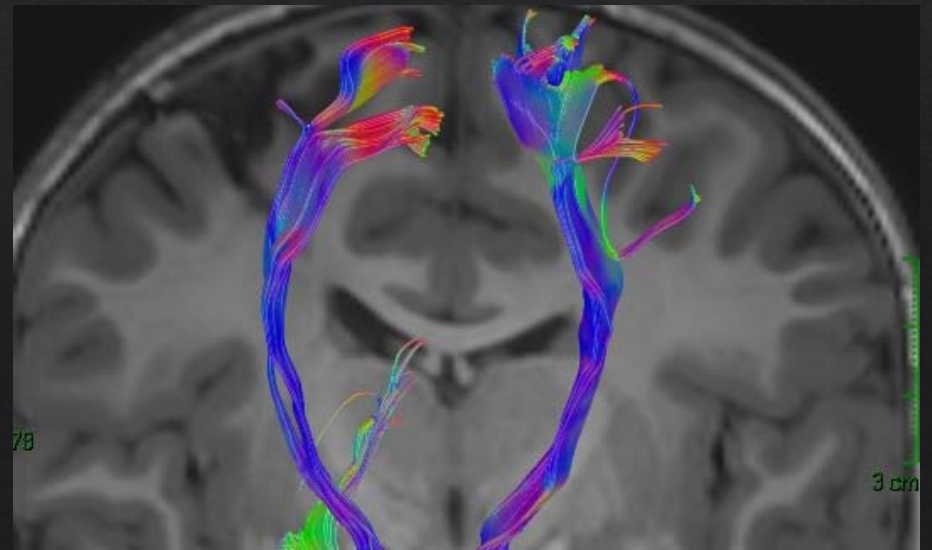
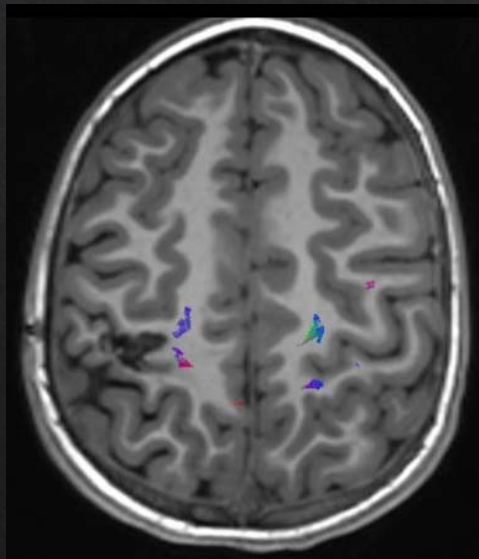
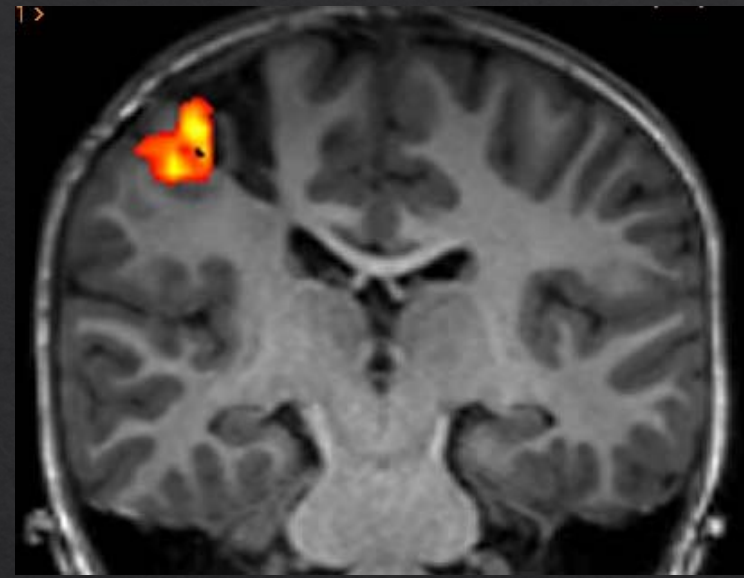
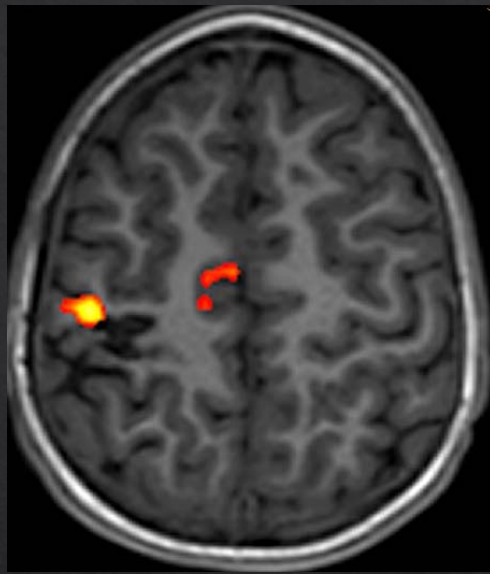


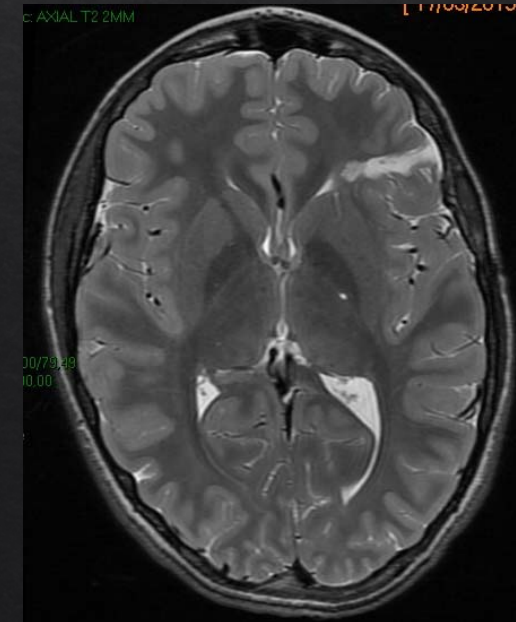
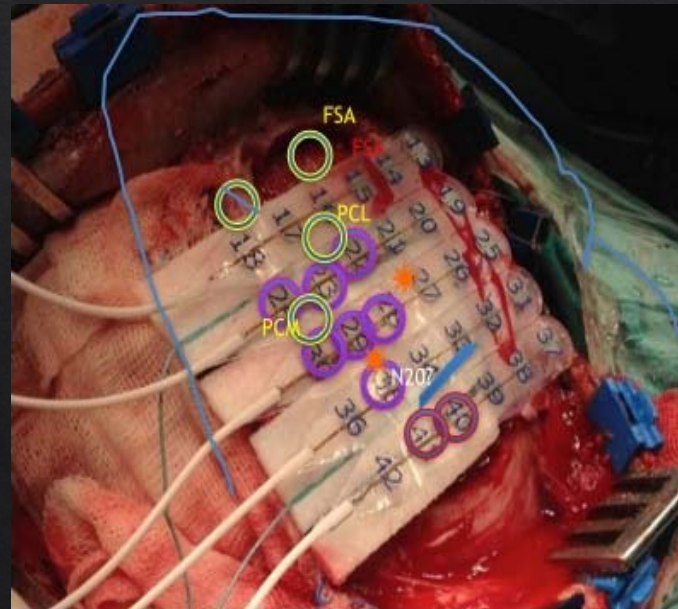
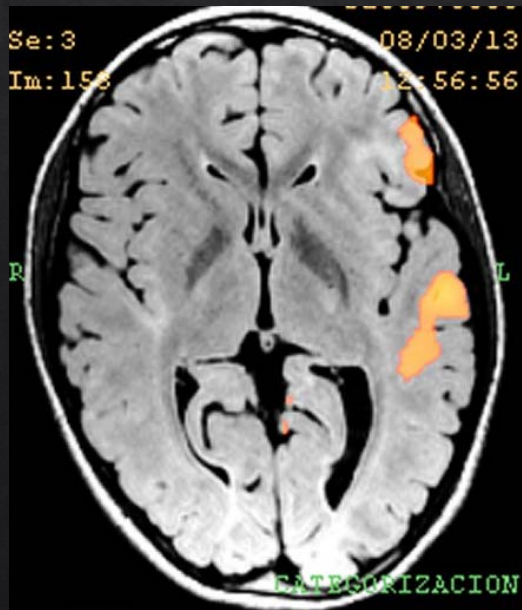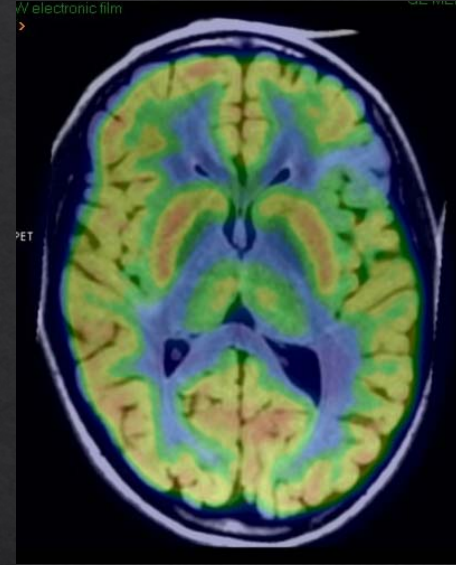
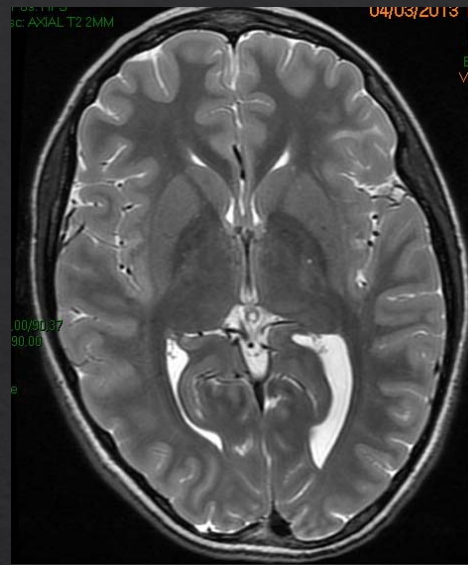
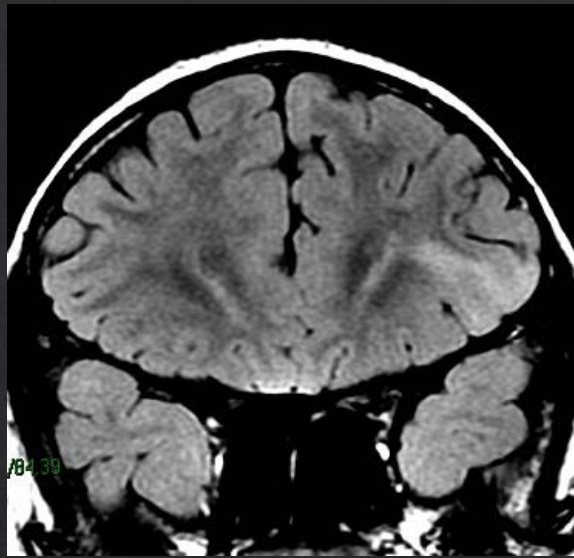
Displasia

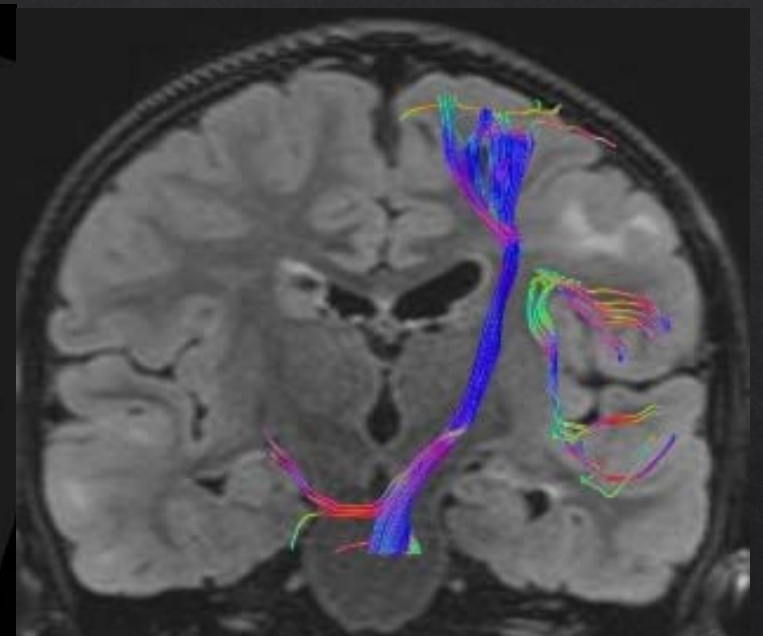
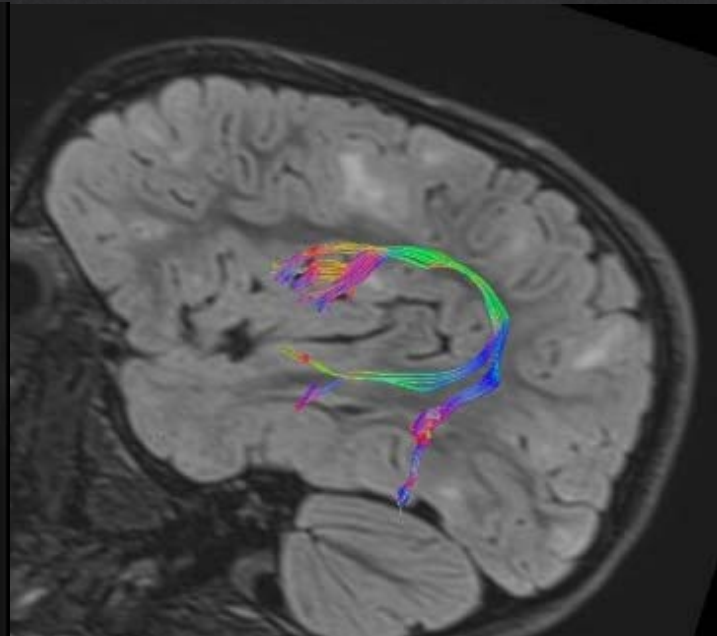
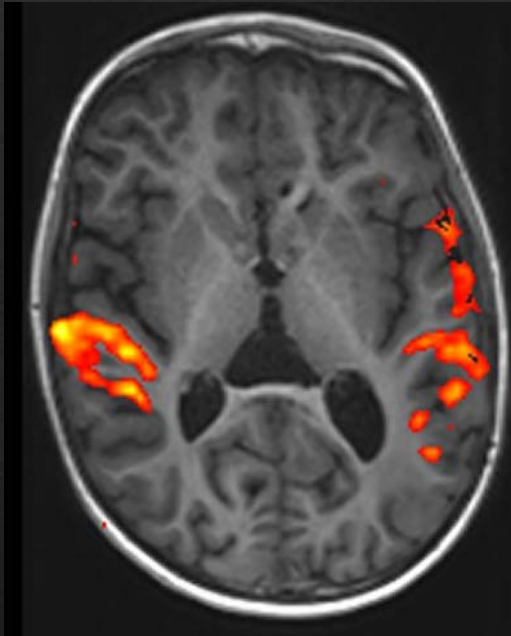


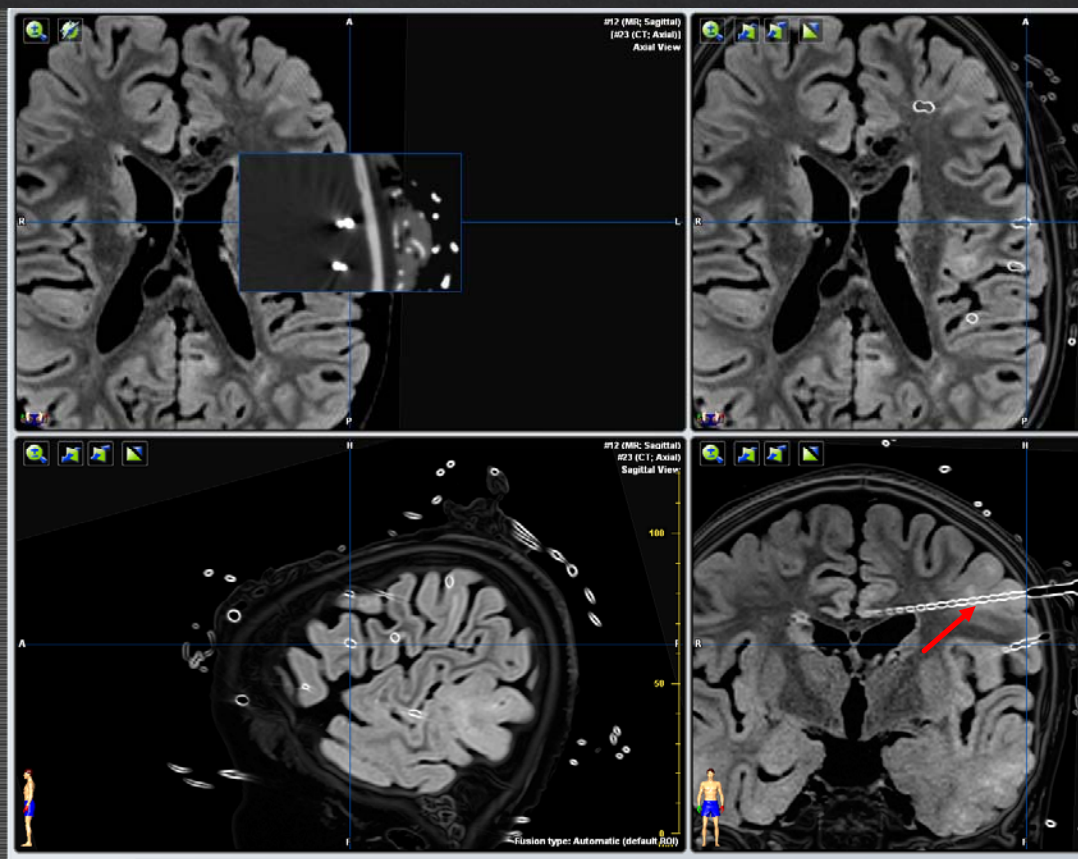
Tracto C-E



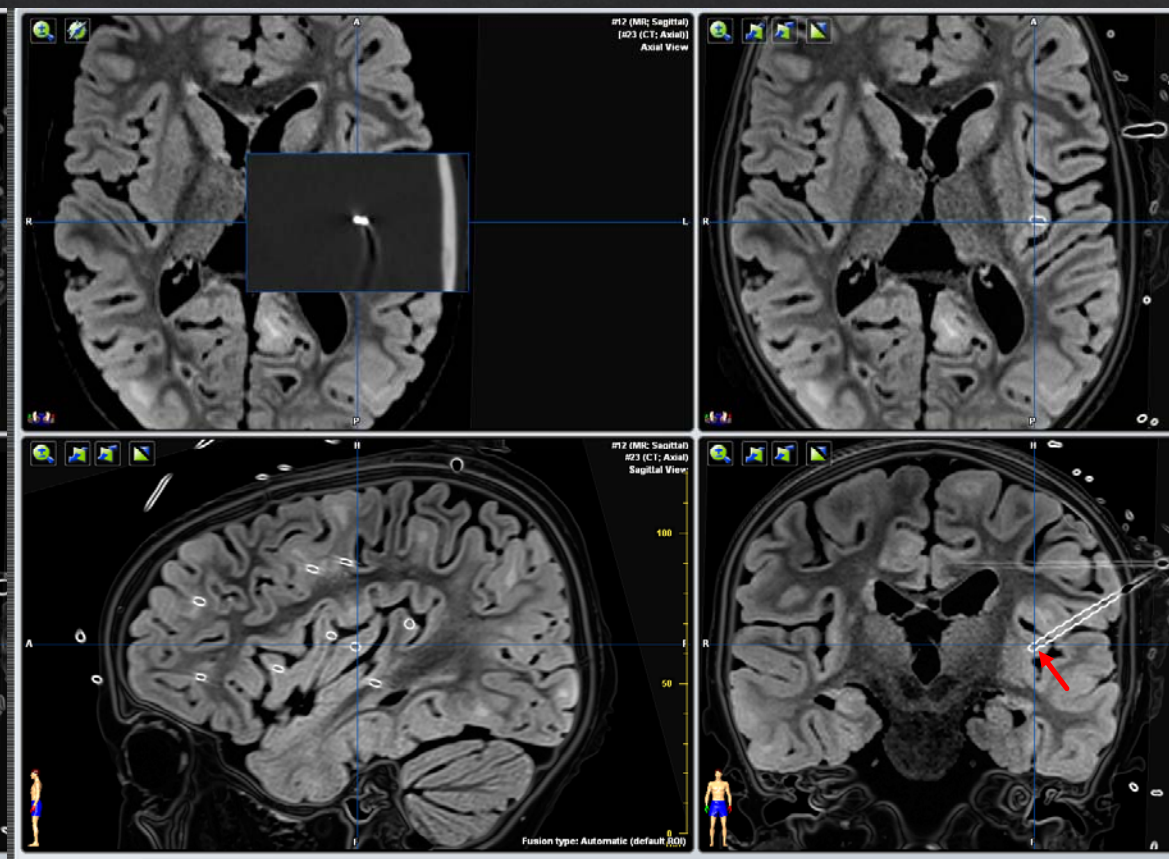




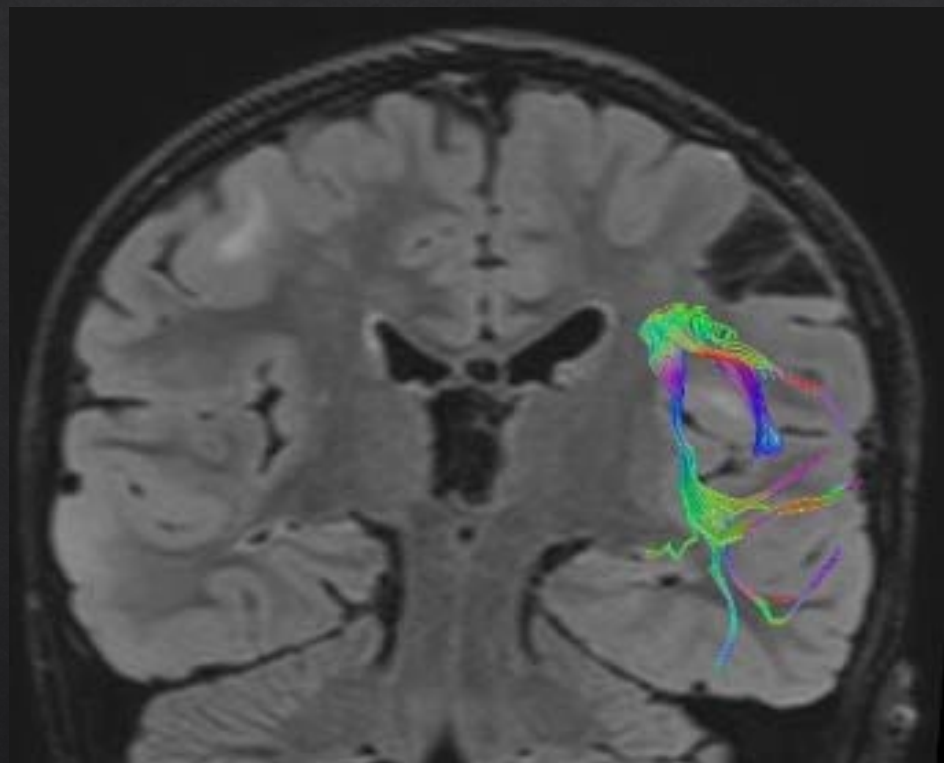
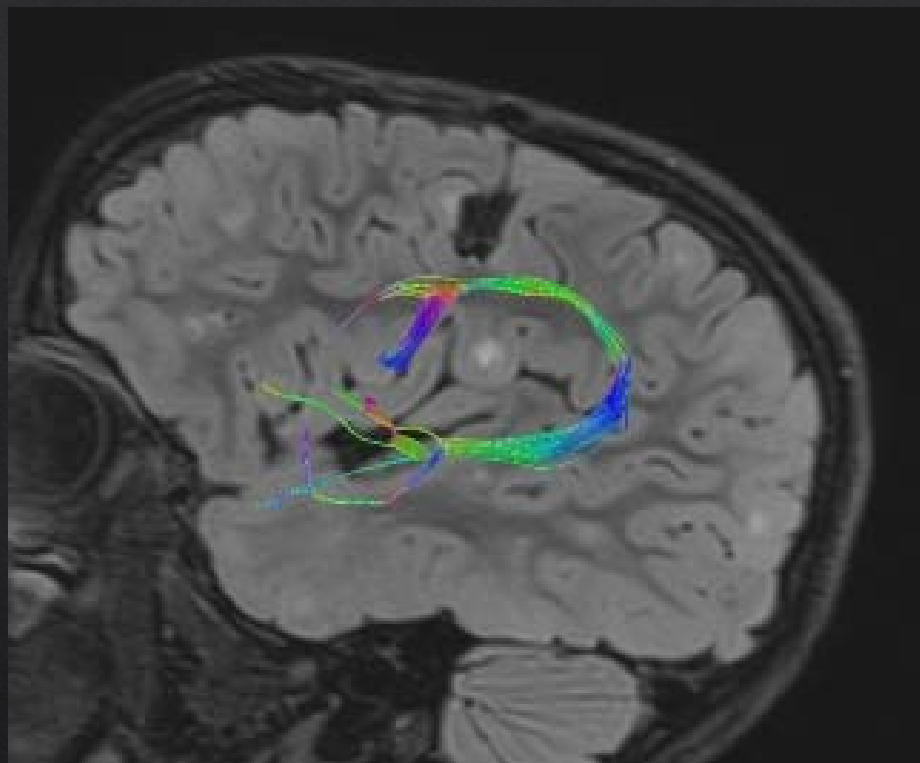


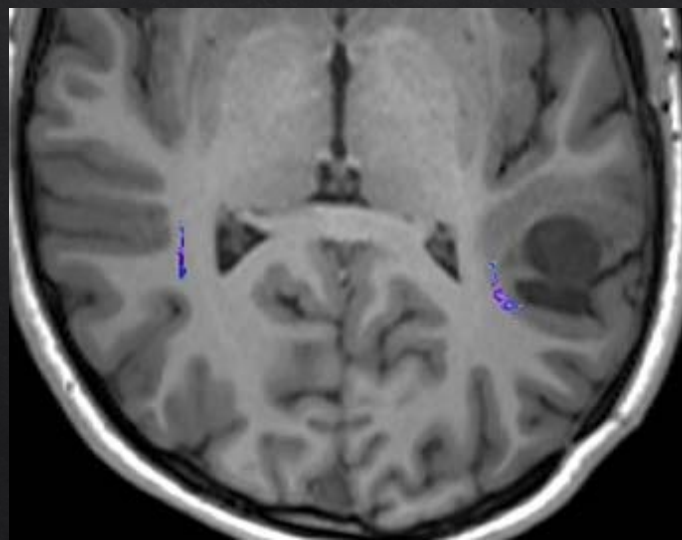
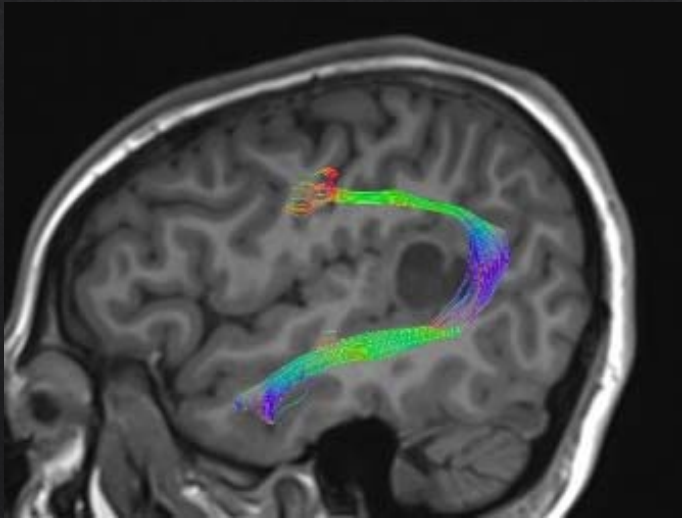
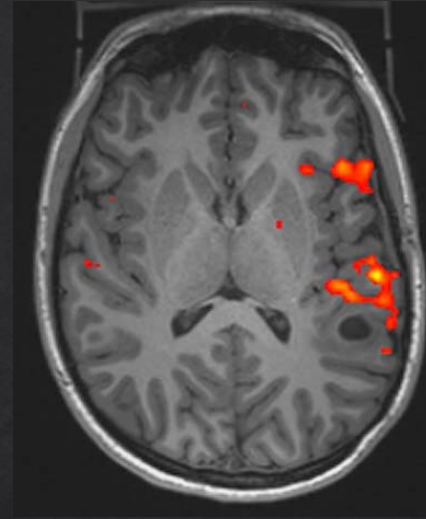
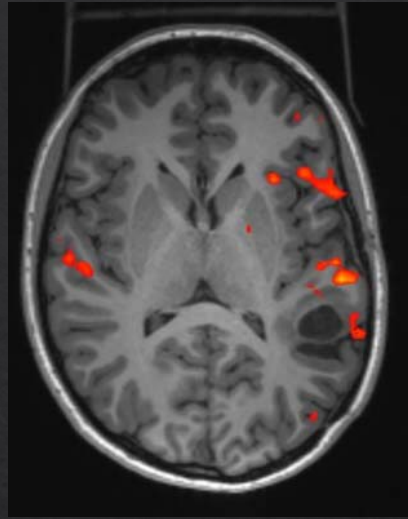
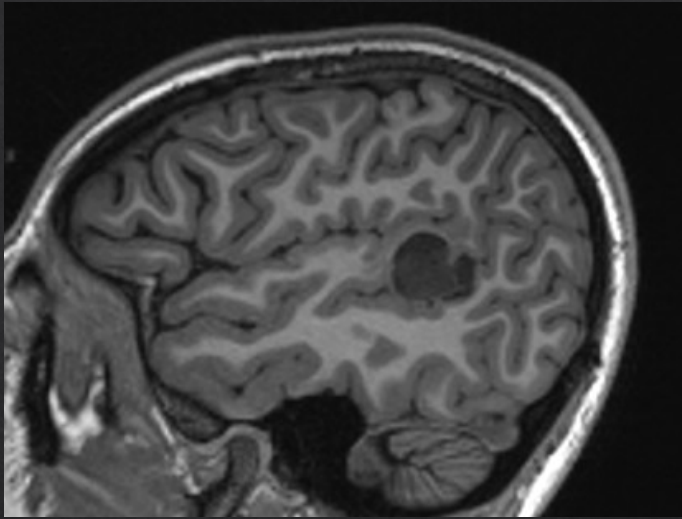






Overview Plan Content

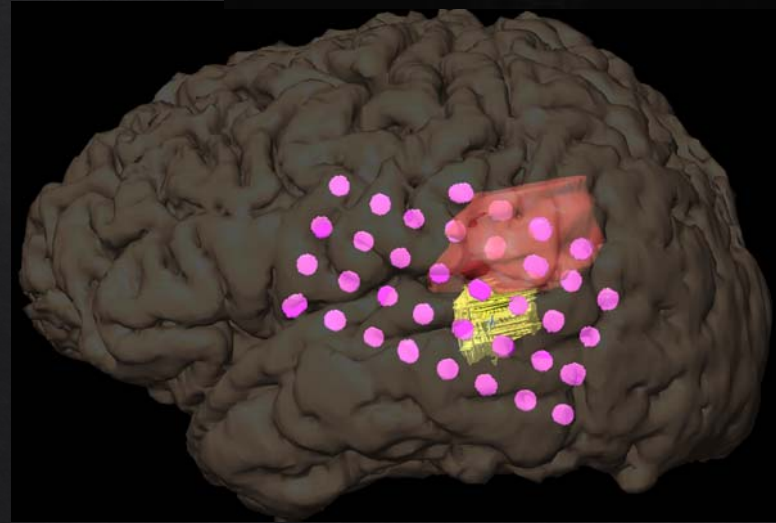
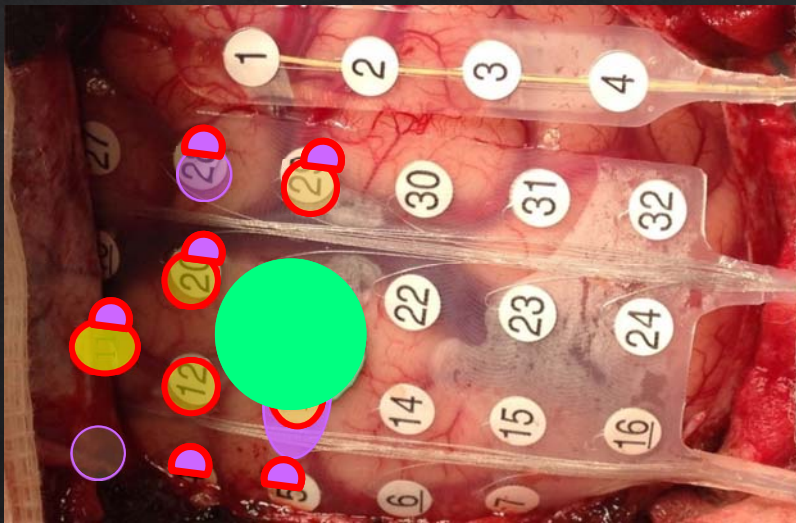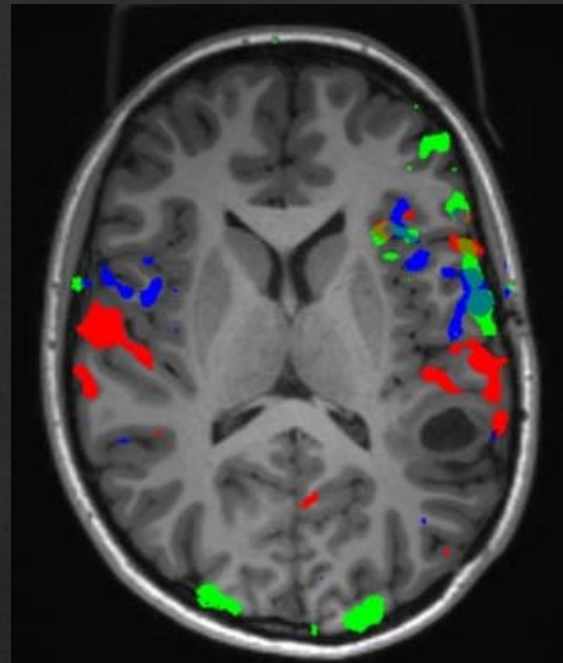


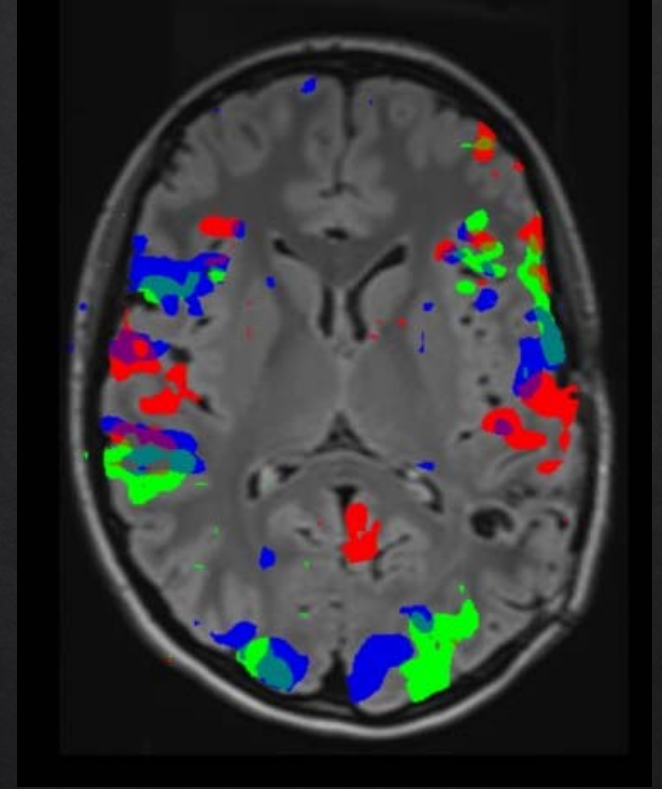
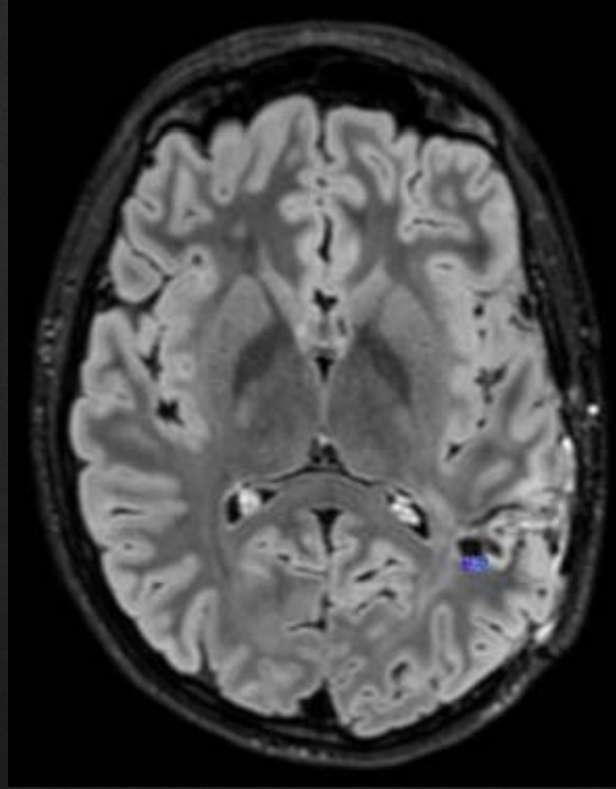
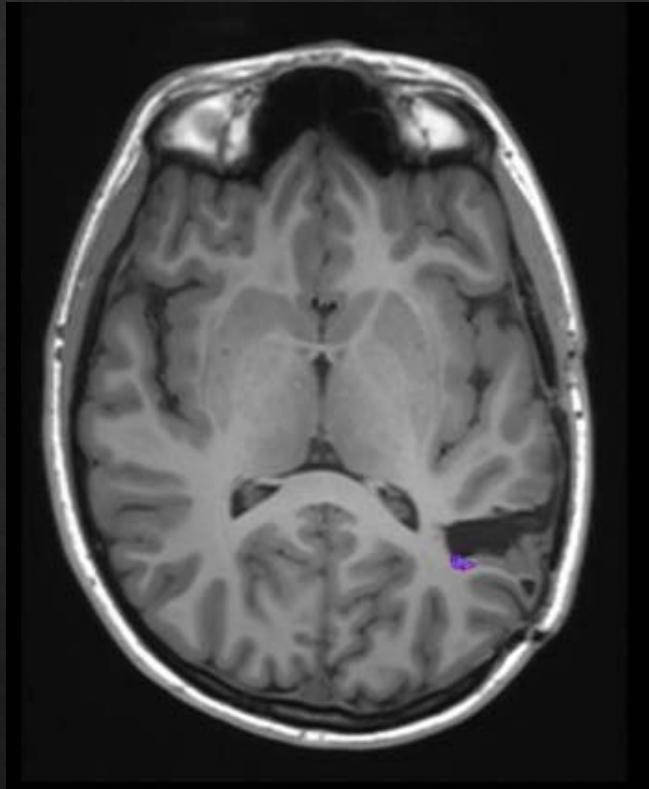
Overview Plan Content





-  Actividad epileptiforme interictal y EEG crítico inicial
-  Respuesta funcional AFASIA+postdescarga + crisis inducida
-  AFASIA sensorial
-  Alexia





Conclusiones

- ◇ Planificación quirúrgica en epilepsia: Multidisciplinar
- ◇ RMf y Tractografía: Complementarias
- ◇ Facilitan resecciones más precisas en áreas elocuentes
- ◇ Disminuyen la necesidad de electrodos subdurales
- ◇ Optimizan la colocación de electrodos profundos
- ◇ Complejidad técnica: imán de 3T, unidades de epilepsia